

# Surgical treatment methods of medication-related osteonecrosis of the jaw. A systematic review

Jonas Zigmantavičius<sup>1</sup>, Gerda Kilinskaitė<sup>2</sup>, Ričardas Kubilius<sup>1</sup>

## SUMMARY

**Objective.** Relevance of the problem and the aim: A variety of surgical treatment modalities are analyzed to treat medication-related osteonecrosis of the jaw, using different adjuvant therapies (fluorescence-guided surgery, autologous platelet concentrates) and thus to improve bone and mucosa healing in the postoperative period and reduce the risk of recurrence of osteonecrosis. The purpose of the present systematic review is to compare the effectiveness of different surgical treatments for medication-related osteonecrosis of the jaw (with applications of autologous platelet concentrates, fluorescence guidance, or without adjuvant measures).

**Materials and methods.** The protocol for the systematic review was prepared according to the PRISMA and Cochrane guidelines for systematic reviews. Electronic databases used: PubMed, The Cochrane Library, Science Direct, Wiley Online Library. The review includes articles investigating surgical treatment methods for medication-related osteonecrosis of the jaw.

**Results.** Twelve scientific articles were included in the review. The studies evaluated the efficacy of autologous platelet concentrates, fluorescence-guided surgery, or standard surgical treatment techniques without adjuvant therapies. The efficiency of curettage, sequestrectomy, and the use of autologous platelet concentrates have been found to range from 80% to 96.7%. The efficiency of fluorescence-guided surgery varied from 83.3% to 94.4%. The highest efficiency range of treatment results was determined by evaluating the surgical treatment without adjuvant therapies, which can reach from 22.22% to 93.2%.

**Conclusions.** The best and most stable results in the surgical treatment of medication-related osteonecrosis of the jaw are achieved by the application of autologous platelet concentrates after surgical removal of necrotic bone or fluorescence-guided surgery.

**Keywords:** medication-related osteonecrosis of the jaw, bisphosphonates, autologous platelet concentrates, fluorescence-guided, treatment.

## INTRODUCTION

Bisphosphonates and denosumab are the most widely used antiresorptive medications intended to inhibit osteoclast activity, prevent bone resorption, and reduce bone loss (1-3). These medications are prescribed to treat Paget's bone disease, osteoporosis, bone metastases, and other rare bone diseases (1, 4). Most often, bisphosphonates are divided according to their composition (containing nitrogen group and non-nitrogen group) and method of administration (used orally and intravenously) (5, 6). Nitrogen-containing

bisphosphonates are more widely used because of their stronger binding to bone hydroxyapatites (5). In the usual treatment of tumor bone diseases, bisphosphonates are used intravenously due to more efficient drug absorption (efficiency reaches 50%), and oral drugs are more often prescribed for the treatment of osteoporosis (absorption of drugs administered in this way reaches 1%) (6, 7). Denosumab is a subcutaneous antibody that binds to and inhibits the bioactive protein (RANKL) while reducing osteoclast formation and activity. It stops bone loss and preserves bone strength (3). Although bisphosphonates or denosumab are prescribed to patients in order to improve their condition, depending on the way, dose, and its final accumulated dose, they can also cause adverse reactions: esophagitis, development of esophageal ulcers, inflammatory reaction, or late side effects, such as

<sup>1</sup>Department of Maxillofacial Surgery, Lithuanian University of Health Sciences, Kaunas, Lithuania

<sup>2</sup>Faculty of Odontology, Lithuanian University of Health Sciences, Kaunas, Lithuania

Address correspondence to Jonas Zigmantavičius, Department of Maxillofacial Surgery, Lithuanian University of Health Sciences, Eivenių g. 2, LT-50161, Kaunas, Lithuania.  
E-mail address: jonas.zigmantav@gmail.com

spontaneous fractures of long bones or osteonecrosis of the jaws (6-9).

Osteonecrosis of the jaw associated with medication occurs in up to 14.8% of cases in patients taking antiresorptive drugs (10). Nowadays, there is a lot of debate about the treatments for MRONJ and the factors that determine their use. In recent years, the superiority of surgical treatment in the early stage compared to conservative treatment has been indicated (11, 12). A variety of surgical treatment methods are analyzed using different adjuvant surgical measures (fluorescence guides, autologous platelet concentrates) to improve the healing of bone tissue and mucosa in the postoperative period and reduce the risk of recurrence of osteonecrosis (13).

The fluorescent guide helps to accurately determine the margins of the bone necrosis zones, ensuring the complete removal of necrotic tissue and reducing the possibility of recurrence (13). Autologous platelet concentrates are characterized by rich growth factors (PDGF, TGF- $\beta$ 1, EGF, VEGF, IGF-I, bFGF, HGF), which stimulate the production of collagen, anti-inflammatory mediators, and initiate cell differentiation. All this helps to heal the wound and reduces the risk of undesirable postoperative complications (14). Thus, until now, the surgical treatment strategy is being questioned and ways to optimize the treatment of MRONJ are being sought.

The purpose of the present systematic review is to compare the effectiveness of different surgical treatments for medication-related osteonecrosis of the jaw (with applications of autologous platelet concentrates, fluorescence guidance, or without adjuvant therapies).

## MATERIALS AND METHODS

### Systematic review protocol

A systematic review was performed in accordance with the guidelines of the PRISMA (Preferred Reporting Items for Systematic Reviews and Meta-Analyses) (15). The research was conducted in electronic databases, including PubMed Medline, Wiley Online Library, The Cochrane Library, and Science Direct from October 12 to December 18, 2020. Databases were searched using the following query: (((((medication OR bisphosphonates) AND (osteonecrosis)) AND (jaw)) AND (surgical)) AND ((treatment) OR (management))).

### Study selection

Scientific databases were searched for articles investigating surgical treatment methods for medication-related osteonecrosis of the jaw, assessing

their effectiveness in percentages (what proportion of subjects recovered after the surgical intervention applied) during the follow-up period. The effectiveness of healing was evaluated, taking into account the changes in clinical and radiological symptoms, and the stage of the disease. The following criteria were analyzed: mucosal healing, bone exposure, infection, and fistula formation.

Clinical studies with humans, published from 2015 to 2020, written in English, and investigating the surgical treatment of medication-related osteonecrosis of the jaw were analyzed in this systematic review. All meta-analyses, systematic and narrative reviews, letters to the editor, case reports or case series, animal and in vitro studies, or those with incomparable results, were excluded.

After applying predefined selection criteria, titles and abstracts were first screened, followed by a full-text review and analysis of full articles.

### Quality assessment

The risk of bias assessment of the included scientific articles was performed using the Cochrane risk assessment tool for randomized trials (RoB 2) (16) and the Newcastle-Ottawa scale (17) for cohort studies.

The risk of bias in randomized trials was determined based on the RoB 2 estimation algorithms. Considering the randomized sequences of the studies, deviation from the planned intervention, missing outcome data, measurement of the outcome, and selective outcomes, the level of systematic risk of the randomized trials was determined (low, medium, or high).

Quality assessment of cohort studies was performed using the Newcastle-Ottawa scale. The criteria for the selection, comparability, and outcome of the articles were evaluated with points, the amount of which indicates the evaluation of the methodological quality of the publications. Articles with 7-9 points are considered high quality, 6-5 points – medium, and less than 5 – low quality.

## RESULTS

### Study selection

The initial database search showed 1211 articles. Systematic literature reviews, meta-analyses, individual clinical case analyses, animal studies, and publications that did not meet the purpose of the systematic review were excluded. After reviewing titles or abstracts, 27 publications were selected for full-text assessment. Articles indicating different treatment efficiency criteria, and investigating preventive and conservative treatment methods were rejected. The systematic review included 12 articles.

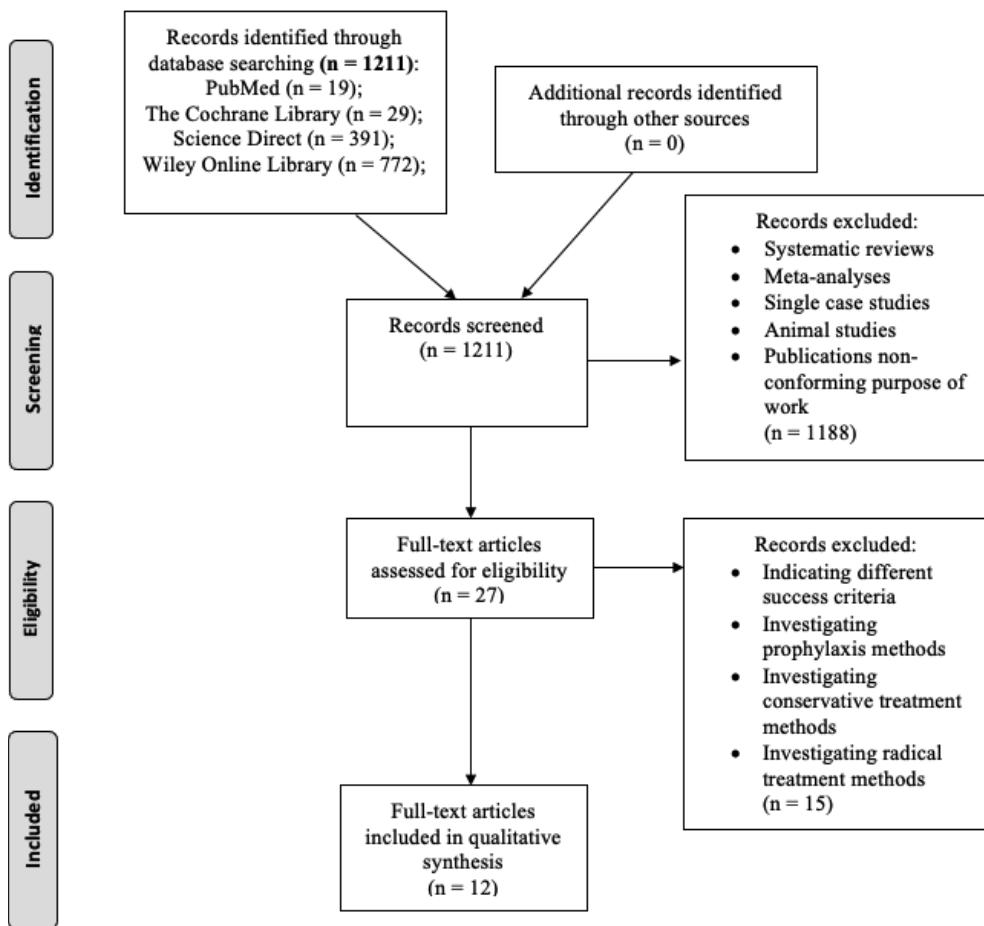


Fig. PRISMA flow diagram

The methodology for searching and selecting articles is indicated in the PRISMA flow diagram (Figure).

**Quality assessment**

Quality assessment of the included articles was performed using the Cochrane (RoB 2) tool for randomized trials (16) and the Newcastle-Ottawa rating scale (17) for evaluating cohort studies. All 3 randomized studies were found to have a moderate level of systematic risk. The assessment is presented in Table 1.

After evaluating the cohort studies, it was found that 4 were high-quality, 5 were medium-quality, and no low-quality publications were identified. The quality assessment of these articles is indicated in Table 2.

Table 1. Quality assessment of articles using the Cochrane (RoB 2) tool

Study	Randomization process	Deviations from Intended Interventions	Missing outcome data	Measurement of the outcome	Selecion of the reported result	Overall
A. Giudice <i>et al.</i> , 2018, (18)	+	-	+	+	+	-
O. Ristow <i>et al.</i> , 2017, (19)	-	-	-	+	+	-
A. Giudice <i>et al.</i> , 2018, (20)	+	-	+	+	+	-

Judgement: “+” – low systemic risk; “-” – moderate systemic risk.

**Study characteristics**

The systematic review included 12 scientific articles: 3 randomized clinical trials (18-20), 4 prospective (21-24), and 5 retrospective (25-29) cohort studies. All articles analyzed the surgical treatment of MRONJ, which involves the removal of necrotic bone. The included publications evaluated the effectiveness of different surgical techniques in the treatment of medication-related osteonecrosis of the jaw: five studies (18, 21-23, 25) evaluated the effect of autologous platelet concentrates, three studies (19, 20, 24) analyzed fluorescence guidance, and four studies (26-29) evaluated conventional surgical treatment techniques without adjuvant measures.

**Characteristics of the subjects**

Patients treated with antiresorptive drugs, with exposed bone or an intraoral or extraoral fistula in the face or jaw, a radiographically proven destructive bone lesion with sequestration, or clinically proven necrotic bone requiring surgical removal were included in the studies.

A review of included scientific articles identified a total of 552 patients with MRONJ. The average age of the patients in the studies ranged from 62.68 to 75.24 years. Patients were mostly diagnosed with stage II MRONJ damage (343 cases). The mandible was the most often affected (417 cases), and the maxilla less frequently (157 cases). The articles also

reported that patients were receiving different bisphosphonates or denosumab. In nine articles (18-22, 25, 26, 28, 29) the method of medication administration is indicated. In these articles, antiresorptive medications are usually administered intravenously (275 cases). The detailed characteristics of the patients are presented in Table 3.

### Characteristics of interventions

In studies, surgical treatment of MRONJ was performed under local or general (20, 21, 23, 25, 28, 29), general (19, 24, 26), local (22) anesthesia, two studies (18, 27) did not specify the method of anesthesia used. The anesthesia method is chosen, taking into account the patient's state of health and the extent of the damage.

During all surgical interventions, after making an incision in the lesion area, the mucoperiosteal flap and necrotic bone were removed by curettage or sequestrectomy (18, 21-23, 25, 27-29) or its resection (19, 20, 24, 26). It is important to mention that in all articles, surgical removal of necrotic bone tissue did not compromise the integrity of the jaws, which would require reconstruction. In ten publications (18, 20-22, 23, 25-29) necrotic bone tissue is removed to the border of viable bone, based on visible bone structure, color, and bleeding. In three studies (19, 20, 24), the boundary was determined using bone fluorescence (viable bone is visible in bright green, and necrotic bone in pale green). In four publications (18, 21, 23, 25) viable bone was covered with PRF

membrane, and in one study (22) PRP was applied. In all articles (18-29), wounds were sutured without tension. After surgery, patients are prescribed analgesics and antibiotics. After the intervention, patients were followed for 1-96 months.

### Treatment outcomes

The effectiveness of surgical treatment of MRONJ in assessing the healing of the mucosa, bone, and signs of infection reaches from 22.22% to 96.7% and it depends on different treatment methods (18-29). It has been found that curettage and sequestrectomy and the use of autologous platelet concentrates have an efficiency of 80% to 96.7% (18, 21-23, 25), during the surgical removal of necrotic bone using a fluorescent guide – from 83.3% to 94.4% (19, 20, 24). The largest range of effectiveness of treatment results was found in the evaluation of surgical treatment of MRONJ without the use of additional measures. During this procedure, the efficiency can reach from 22.22% up to 93.2% (18, 26-29).

Only two studies evaluating the effectiveness of PRF application on the healing of MRONJ after surgical removal of necrotic bone tissue found a statistically significant positive effect of PRF compared to surgical treatment without additional measures ( $P < 0.05$ ) (18, 25).

Comparing different guides (autofluorescent with tetracycline fluorescent) and surgical treatment with and without an autofluorescent guide was not statistically significant difference found in studies

**Table 2.** Quality assessment of articles using the Newcastle-Ottawa rating scale

Study	Selection				Comparability (++)	Outcome			Total
	1* (+)	2* (+)	3* (+)	4* (+)		5* (+)	6* (+)	7* (+)	
J. H. Park <i>et al.</i> , 2017, (21)	+	+	+	+	++	+	+	+	9
R. Mauceri <i>et al.</i> , 2018, (22)	+		+	+	+	+	+	+	7
S. E. Nørholt ir J. Hartlev, 2016, (23)	+		+	+	+	+	+	+	7
S. Otto <i>et al.</i> , 2016, (24)	+		+	+	+	+	+	6	
S. Szentpeteri <i>et al.</i> , 2020, (25)	+		+	+	+	+	+	6	
J. P. Bodem <i>et al.</i> , 2016, (26)	+		+	+	+	+	+	6	
Y. Guo ir C. Guo, 2020, (27)	+	+	+	+	+	+		6	
S. E. C. Pichardo <i>et al.</i> , 2016, (28)	+		+	+	+	+	+	6	
M. Nisi <i>et al.</i> , 2018, (29)	+		+	+	+	+	+	+	7

\* – Explanation. Selection criteria: 1 – representative of the exposed cohort, 2 – selection of external control, 3 – ascertainment of exposure, 4 – outcome of interest not present at the start of the study; Outcome criteria: 5 – assessment of outcomes, 6 – sufficient follow-up time, 7 – adequacy of follow-up.

**Table 3.** Data selection

Study	Number of patients (areas)	Stage (number of patients)	Jaw part (number of patients)	Patients average age (age ranges)	The main diseases (number of patients)	Medication used (number of patients)	Administration of medication (number of patients)	Duration of medication use (months)
A. Giudice <i>et al.</i> , 2018, (18)	47 (61)	II (27), III (20)	Mandible (49), maxilla (12)	74.7±6.5	Osteoporosis (12), prostate cancer (15), breast cancer (11), kidney cancer (5), lung cancer (3), multiple myeloma (1)	Zoledronate (26), Alendronate (10), Denosumab (10), Ibandronate (1)	Intravenous (26), oral (11), subcutaneous (10)	-
O. Ristow <i>et al.</i> , 2017, (19)	40 (51)	I (4), II (41), III (6)	Mandible (33), maxilla (18)	71.8±9.4	Breast cancer (18), prostate cancer (10), osteoporosis (6), multiple myeloma (4), other cancers (2)	BP(32), BP ir Dmab (8)	Intravenous (33), oral (5), intravenous and oral (2)	47.1±27.7
A. Giudice <i>et al.</i> , 2018, (20)	36 (39)	I (12), II (2), III (12)	Mandible (26), maxilla (7), both (3)	72.14±8.9	Osteoporosis (13), breast cancer (7), prostate cancer (9), multiple myeloma (4), other cancers (3)	Zoledronate (14), Alendronate (12), Denosumab (6), Risedronate (1), Clondronate (1), several medications (2)	Intravenous (14), oral (13), subcutaneous (6), intramuscular (1), intravenous and subcutaneous (1), oral and intramuscular (1)	-
J. H. Park <i>et al.</i> , 2017, (21)	55	I (8), II (43), III (4)	Mandible (37), maxilla (16), both (2);	75.2-75.24 (59-97)	Osteoporosis (48), Metastases in the bones (7)	Alendronate (30), Risedronate (7), Ibandronate (6), Pamidronate (3), Zoledronate (1), several medication (8)	Intravenous (48), oral (7)	48.32-59.73 (12-180)
R. Mauceri <i>et al.</i> , 2018, (22)	10	I (6), II (4)	Mandible (9), maxilla (1)	75.2±5.94	Multiple myeloma (7), prostate cancer (3), breast cancer (3)	Zoledronate (9), Ibandronate (1)	Intravenous (10)	31.8±25.76
S. E. Nørholt ir J. Hartlev, 2016, (23)	15	II (13), III (2)	Mandible (11), maxilla (3), both (1)	68.5 (54-83)	Metastases in the bones (8), osteoporosis (7)	Alendronate (5), Denosumab (4), Zoledronate (4), Ibandronate (1), Pamidronate (1)	-	High dose 34 (15-73), low dose 126 (48-240)
S. Otto <i>et al.</i> , 2016, (24)	54 (65)	0 (1), I (14), II (42), III (8)	Mandible (40), maxilla (25)	71.4±9.2 (45-91)	Breast cancer (20), prostate cancer (16), osteoporosis (9), multiple myeloma (4), other cancers (5)	Zoledronate (40), Alendronate (5), Denosumab (3), Ibandronate (2), BP and Dmab (4)	-	46.3±31.8
S. Szentpeteri <i>et al.</i> , 2020, (25)	101	II (77), III (24)	Mandible (68), maxilla (27), both (6)	63.97-68.42	Breast cancer (41), prostate cancer (18), osteoporosis (15), multiple myeloma (12), kidney cancer (3), other cancers (12)	BP (101)	Intravenous (71), oral (26), not specified (4)	-
J. P. Bodem <i>et al.</i> , 2016, (26)	39 (47)	II (23), III (24)	Mandible (34), maxilla (13)	72±9	-	Zoledronate (39)	Intravenous (39)	24 (2-120)
Y.Guo ir C.Guo, 2020, (27)	28	II (10), III (18)	Mandible (13), maxilla (12), both (3)	62.68 (44-83)	-	Zoledronate, Pamidronate	-	37.21±26.34
S. E. C. Pichardo <i>et al.</i> , 2016, (28)	74	II (22), III (52)	Mandible (58), maxilla (11), both (5)	67.9 (26-91)	Osteoporosis (42), breast cancer (18), multiple myeloma (6), prostate cancer (5)	Pamidronate (23), Alendronate (30), Zoledronate (10), Risedronate (9), Ibandronate (1)	Intravenous (34), oral (40)	12-120
M. Nisi <i>et al.</i> , 2018, (29)	53	I (7), II (39), III (7)	Mandible (39), maxilla (12), both (2)	71.9±10.2 (41-87)	Osteoporosis (53)	Alendronate (45), Ibandronate (5), Risedronate (3)	Oral (53)	-

( $P > 0.05$ ) (19, 20). Detailed results are presented in the Table 4.

## DISCUSSION

The best results were achieved in the study by J.H. Park *et al.* (21) with surgical treatment with L-PRF and BMP-2. During this study, effective treat-

ment was achieved in 96.7% of patients (21). It was also found that curettage, sequestrectomy, L-PRF, and BMP-2 application statistically significantly improved MRONJ healing compared to curettage, sequestrectomy, and L-PRF without BMP-2 application. Inhibition of bone tissue remodeling is one of the main mechanisms of MRONJ pathogenesis, and BMP-2 has a potential opposite-osteoinductive, bone

**Table 4.** Treatment outcomes

Study	Study design	Method of treatment (n)	Follow-up period (months)	Outcomes	Significance (P)
A. Giudice <i>et al.</i> , 2018, (18)	Randomized clinical trial	Curettage and PRF application (24) / Curettage (23)	12	In the curettage and PRF group, complete recovery after 1 month reached 87.5%, after 6 months 95.8%, after 12 months 95.8%; In the curettage group, complete recovery after 1 month. reached 60.9%, after 6 months 82.6%, after 12 months. 91.3%.	$P < 0.05$ after 1 month
O. Ristow <i>et al.</i> , 2017, (19)	Randomized clinical trial	Resection of necrotic bone tissue using an autofluorescence guide (20) / Removal of necrotic bone tissue using a tetracycline fluorescence guide (20)	6- 12	Using the autofluorescence guide, complete healing of the mucosa after 6 months was observed in 88.9% of patients, in the tetracycline fluorescent guide group, the mucosa completely healed in 84.2% of patients.	$P > 0.05$
A. Giudice <i>et al.</i> , 2018, (20)	Randomized clinical trial	Resection of necrotic bone tissue using an autofluorescence guide (18)/ Resection of necrotic bone tissue (18)	6-12	Using the autofluorescence guide, complete healing of the mucosa after 6 months was observed in 83.3% of patients; without the use of an autofluorescence guide, healing was observed in 88.2% of patients.	$P > 0.05$
J. H. Park <i>et al.</i> , 2017, (21)	Prospective cohort study	Curettage/ sequestrectomy with BMP-2 + L-PRF application (30)/ curettage/ sequestrectomy with L-PRF (25)	6	In the BMP-2 + L-PRF group, the success rate was 96.7% (complete healing at 4 weeks was 60.0%, delayed healing (after 16 weeks) 36.7%, no healing 3.3%); In the L-PRF group, the success rate was 88% (complete healing after 4 weeks was 36.0%, delayed healing (after 16 weeks) 52.0%, no healing 12%).	$P = 0.028$
R. Mauceri <i>et al.</i> , 2018, (22)	Prospective cohort study	Curettage, sequestrectomy (laser) and PRP application	12	Treatment success rate 80% (30% complete recovery, 50% improvement), 20% showed no clinical improvement.	-
S. E. Nørholt ir J. Hartlev, 2016, (23)	Prospective cohort study	Curettage and PRF application	7-20	During the follow-up period, recovery was 93%.	-
S. Otto <i>et al.</i> , 2016, (24)	Prospective cohort study	Resection of necrotic bone tissue using an autofluorescence guide	12.9 (1-39)	Using the autofluorescence guide, complete healing of the mucosa was achieved in 94.4% of patients.	-
S. Szentpeteri <i>et al.</i> , 2020, (25)	Retrospective cohort study	Curettage, sequestrectomy and PRF (28) / Curettage, sequestrectomy (73)	12	In the curettage, sequestrectomy and PRF group, recovery was 82.14%. Healing was established in the curettage and sequestrectomy group 58.46% of cases.	$P = 0.022$
J. P. Bodem <i>et al.</i> , 2016, (26)	Retrospective cohort study	Resection of necrotic bone tissue	12 weeks	After 12 weeks, the effectiveness of surgical treatment was 74.5%.	-
Y. Guo ir C. Guo, 2020, (27)	Retrospective cohort study	Sequestrectomy and curettage (18)/ sequestrectomy, curettage and cortical bone perforations (8)	30	The effectiveness after 30 months was 22.22% for sequestrectomy and curettage, and 80% for sequestrectomy, curettage and cortical perforations.	$P = 0.005$
S. E. C. Pichardo <i>et al.</i> , 2016, (28)	Retrospective cohort study	Sequestrectomy and curettage	6-96	With this surgical approach, the treatment was effective in 93.2% of patients with a follow-up of at least 6 months.	-
M. Nisi <i>et al.</i> , 2018, (29)	Retrospective cohort study	Curettage, sequestrectomy	24	6 months after conservative surgical treatment, the efficiency reached 84.9%.	-

remodeling-promoting effect. In this way, the differentiation of osteoblasts and osteoclasts is promoted and a more successful treatment result is ensured. However, the method and dose of BMP-2 administration that most effectively promotes bone remodeling have not yet been fully elucidated (30-32).

The lowest results were found in the study by Y. Guo and C. Guo (27), during which the successful healing rate of MRONJ surgical treatment without additional measures reached 22.22%. In the study, the majority of patients (14 out of 18) had stage III MRONJ, which is particularly difficult to treat and is often insufficient for surgical treatment without adjuvant therapies.

Two studies found statistically significantly better MRONJ healing outcomes with PRF compared to surgical removal without additional measures ( $P < 0.05$ ) (18, 25). A. Giudice and colleagues (18) found a statistically significant positive effect of PRF only one month after surgery, while Szentpeteri and colleagues (25) found a statistically significant positive effect of PRF during the entire follow-up period (12 months) ( $P < 0.05$ ). Other involved studies did not evaluate statistical significance on PRF application.

Analyzing the influence of bone fluorescence on the surgical treatment of MRONJ, no statistically significant difference ( $P > 0.05$ ) was found in studies (19, 20) comparing different guides (autofluorescent with tetracycline fluorescent) (19) and surgical treatment with and without an autofluorescent guide (20). However, scientific publications analyzing histological specimens of resected bone indicate that fluorescence-guided surgery can more accurately delineate the margins between necrotic and viable bone than visual signs of viable bone (33, 34). The use of bone fluorescence to objectively assess the margin of viable and necrotic bone in surgically treated MRONJ patients appears to be a promising approach.

A study analyzing the effectiveness of surgical treatment of MRONJ with and without cortical perforations showed a statistically significant difference between these techniques ( $P < 0.05$ ) (27). Perforations of the cortical layer of the bone achieve significantly better healing results (27). Perforations in the cortical layer of the bone make the sufficient supply of blood, which ensures the delivery of oxygen, nutrients, hormones, and growth factors, which can reduce the risk of infection and promote the wound healing process (27).

J. H. Park *et al.* (21) in their study found that the presence of bacterial colonies in the wound area had a statistically significant effect on the healing process ( $P = 0.017$ ). Scientific articles indicate that *Actinomyces* are most commonly found in MRONJ affected areas

(from 46.75% to 68.8% of cases) (35, 36). In the article also mentioned other, often found bacterial colonies: *Streptococcus*, *Candida*, *Staphylococcus*, *Klebsiella*, *Eikenella*, *Haemophilus*, *Fusobacterium*, and *Escherichia* (35). Although the influence of bacterial colonization on the development of MRONJ has not been fully elucidated, it has been found that the use of antiresorptive medications containing a nitrogen group increases bacterial colonization in the wound area and thus promotes the development of infection and the progression of MRONJ (35).

J.H. Park *et al.* (21) did not indicate a statistically significant relationship between the healing of MRONJ and patients' gender, age (older or younger than 75 years), the factor that initiated osteonecrosis, duration of antiresorptive medication use (more or less than 40 months), stage, CTX level (more or less than 150 pg/ml). According to clinical studies, it is established that the CTX indicator is not accurate in predicting the development of MRONJ in an individual patient, but it helps to identify patients in the risk group (when the value of the CTX indicator is less than 150 pg/ml) (37- 39).

J.P. Bodem *et al.* (26) revealed that drug holidays had no statistically significant effect on healing results ( $P > 0.05$ ). However, other studies have shown that discontinuing BP leads to statistically significantly better surgical outcomes ( $P < 0.05$ ) (40, 41). In a scientific article by Y. H. Kim *et al.* (40), it is suggested that in order to avoid failure of surgical treatment of MRONJ, drug holiday should last at least 4 months before surgery.

The included studies did not find a significant difference ( $P > 0.05$ ) between healing success and the method of administration of antiresorptive medications (oral or injectable) (20, 21). However, clinical studies declare that the total cumulative dose and effect of injectable medications are stronger due to more efficient absorption of the medication (6, 42).

However, there is a lack of homogenous clinical studies independently evaluating effectiveness of different surgical treatments for MRONJ based on the initial stage, co-morbidities, and additional medications.

## CONCLUSIONS

In conclusion, the use of autologous platelet concentrates could have a beneficial effect on the surgical treatment outcome of MRONJ.

## STATEMENT OF CONFLICTS OF INTEREST

The authors state no conflict of interest.

## REFERENCES

1. Cremers S, Drake MT, Ebetino FH, Bilezikian JP, Russell RGG. Pharmacology of bisphosphonates. *Br J Clin Pharmacol* 2019;85(6):1052-62.
2. Ata-Ali J, Ata-Ali F, Peñarrocha-Oltra D, Galindo-Moreno P. What is the impact of bisphosphonate therapy upon dental implant survival? A systematic review and meta-analysis. *Clin Oral Implants Res* 2016;27(2):e38-46.
3. Baron R, Ferrari S, Russell RGG. Denosumab and bisphosphonates: different mechanisms of action and effects. *Bone* 2011;48(4):677-92.
4. Corral-Gudino L, Tan AJ, Del Pino-Montes J, Ralston SH. Bisphosphonates for Paget's disease of bone in adults. *Cochrane Database Syst Rev* 2017;12:CD004956.
5. Ganapathy N, Gokulnathan S, Balan N, Maheswaran T, Venkatesan. Bisphosphonates: An update. *J Pharm Bioallied Sci* 2012;4(Suppl 2):S410-3.
6. Fazil M, Baboota S, Sahni JK, Ameenuzzafar, Ali J. Bisphosphonates: therapeutics potential and recent advances in drug delivery. *Drug Deliv* 2015;22(1):1-9.
7. Aderibigbe B, Aderibigbe I, Popoola P. Design and biological evaluation of delivery systems containing bisphosphonates. *Pharmaceutics* 2016;9(1):2.
8. Di Nisio C, Zizzari VL, Zara S, Falconi M, Teti G, Tetè G, et al. RANK/RANKL/OPG signaling pathways in necrotic jaw bone from bisphosphonate-treated subjects. *Eur J Histochem* 2015;59(1):2455.
9. Ilyas Z, Camacho PM. Rare adverse effects of bisphosphonate therapy. *Curr Opin Endocrinol Diabetes Obes* 2019;26(6):335-8.
10. Yamazaki T, Yamori M, Ishizaki T, Asai K, Goto K, Takahashi K, et al. Increased incidence of osteonecrosis of the jaw after tooth extraction in patients treated with bisphosphonates: a cohort study. *Int J Oral Maxillofac Surg* 2012;41(11):1397-403.
11. Ruggiero SL, Dodson TB, Fantasia J, Goodday R, Aghaloo T, Mehrotra B, et al. American Association of Oral and Maxillofacial Surgeons position paper on medication-related osteonecrosis of the jaw--2014 update. *J Oral Maxillofac Surg* 2014;72(10):1938-56.
12. Giudice A, Barone S, Diodati F, Antonelli A, Nocini R, Cristofaro MG. Can surgical management improve resolution of medication-related osteonecrosis of the jaw at early stages? A prospective cohort study. *J Oral Maxillofac Surg* 2020;78(11):1986-99.
13. Beth-Tasdogan NH, Mayer B, Hussein H, Zolk O. Interventions for managing medication-related osteonecrosis of the jaw. *Cochrane Database Syst Rev* 2017;10:CD012432.
14. Lopez-Jornet P, Sanchez Perez A, Amaral Mendes R, Tobias A. Medication-related osteonecrosis of the jaw: Is autologous platelet concentrate application effective for prevention and treatment? A systematic review. *J Craniomaxillofac Surg* 2016;44(8):1067-72.
15. Moher D, Shamseer L, Clarke M, Ghersi D, Liberati A, Petticrew M, et al. Preferred reporting items for systematic review and meta-analysis protocols (PRISMA-P) 2015 statement. *Syst Rev* 2015;4(1):1.
16. Sterne JAC, Savović J, Page MJ, Elbers RG, Blencowe NS, Boutron I, et al. RoB 2: a revised tool for assessing risk of bias in randomised trials. *BMJ* 2019;366:14898.
17. Cook DA, Reed DA. Appraising the quality of medical education research methods: the Medical Education Research Study Quality Instrument and the Newcastle-Ottawa Scale-Education: The medical education research study quality instrument and the Newcastle-Ottawa scale-education. *Acad Med* 2015;90(8):1067-76.
18. Giudice A, Barone S, Giudice C, Bennardo F, Fortunato L. Can platelet-rich fibrin improve healing after surgical treatment of medication-related osteonecrosis of the jaw? A pilot study. *Oral Surg Oral Med Oral Pathol Oral Radiol* 2018;126(5):390-403.
19. Ristow O, Otto S, Geiß C, Kehl V, Berger M, Troeltzsch M, et al. Comparison of auto-fluorescence and tetracycline fluorescence for guided bone surgery of medication-related osteonecrosis of the jaw: a randomized controlled feasibility study. *Int J Oral Maxillofac Surg* 2017;46(2):157-66.
20. Giudice A, Bennardo F, Barone S, Antonelli A, Figliuzzi MM, Fortunato L. Can autofluorescence guide surgeons in the treatment of medication-related osteonecrosis of the jaw? A prospective feasibility study. *J Oral Maxillofac Surg* 2018;76(5):982-95.
21. Park J-H, Kim J-W, Kim S-J. Does the addition of bone morphogenetic protein 2 to platelet-rich fibrin improve healing after treatment for medication-related osteonecrosis of the jaw? *J Oral Maxillofac Surg* 2017;75(6):1176-84.
22. Mauceri R, Panzarella V, Maniscalco L, Bedogni A, Licata ME, Albanese A, et al. Conservative surgical treatment of bisphosphonate-related osteonecrosis of the jaw with Er,Cr:YSGG laser and platelet-rich plasma: A longitudinal study. *Biomed Res Int* 2018;2018:3982540.
23. Nørholt SE, Hartlev J. Surgical treatment of osteonecrosis of the jaw with the use of platelet-rich fibrin: a prospective study of 15 patients. *Int J Oral Maxillofac Surg* 2016;45(10):1256-60.
24. Otto S, Ristow O, Pache C, Troeltzsch M, Fliefel R, Ehrenfeld M, et al. Fluorescence-guided surgery for the treatment of medication-related osteonecrosis of the jaw: A prospective cohort study. *J Craniomaxillofac Surg* 2016;44(8):1073-80.
25. Szentpeteri S, Schmidt L, Restar L, Csaki G, Szabo G, Vaszilko M. The effect of platelet-rich fibrin membrane in surgical therapy of medication-related osteonecrosis of the jaw. *J Oral Maxillofac Surg* 2020;78(5):738-48.
26. Bodem JP, Schaal C, Kargus S, Saure D, Mertens C, Engel M, et al. Surgical management of bisphosphonate-related osteonecrosis of the jaw stages II and III. *Oral Surg Oral Med Oral Pathol Oral Radiol* 2016;121(4):367-72.
27. Guo Y, Guo C. Enhancement of bone perfusion through cortical perforations to improve healing of medication-related osteonecrosis of the jaw: a retrospective study. *Int J Oral Maxillofac Surg* 2021;50(6):740-74.
28. Pichardo SEC, Kuijpers SCC, van Merkesteyn JPR. Bisphosphonate-related osteonecrosis of the jaws: Cohort study of surgical treatment results in seventy-four stage II/III patients. *J Craniomaxillofac Surg* 2016;44(9):1216-20.
29. Nisi M, Karapetsa D, Gennai S, Ramaglia L, Graziani F, Gabriele M. Conservative surgical treatment of medication related osteonecrosis of the jaw (MRONJ) lesions in patients affected by osteoporosis exposed to oral bisphosphonates: 24 months follow-up. *J Craniomaxillofac Surg* 2018;46(7):1153-8.
30. Cano-Durán JA, Peña-Cardelles J-F, Ortega-Concepción D, Paredes-Rodríguez VM, García-Riart M, López-Quiles J. The role of Leucocyte-rich and platelet-rich fibrin (L-PRF) in the treatment of the medication-related osteonecrosis of the jaws (MRONJ). *J Clin Exp Dent* 2017;9(8):e1051-9.
31. El Bialy I, Jiskoot W, Reza Nejadnik M. Formulation, delivery and stability of bone morphogenetic proteins for effective bone regeneration. *Pharm Res* 2017;34(6):1152-70.
32. Nguyen HT, Ono M, Oida Y, Hara ES, Komori T, Akiyama K, et al. Bone marrow cells inhibit BMP-2-induced osteo-



- blast activity in the marrow environment: Bone marrow cells inhibit bmp-2-induced osteoblast activity. *J Bone Miner Res* 2019;34(2):327-32.
33. Tomo S, da Cruz TM, Figueira JA, Cunha JLS, Miyahara GI, Simonato LE. Fluorescence-guided surgical management of medication-related osteonecrosis of the jaws. *Photodiagnosis Photodyn Ther* 2020;32(102003):102003.
  34. Wehrhan F, Weber M, Neukam FW, Geppert C-I, Kesting M, Preidl RHM. Fluorescence-guided bone resection: A histological analysis in medication-related osteonecrosis of the jaw. *J Craniomaxillofac Surg* 2019;47(10):1600-7.
  35. Hinson AM, Smith CW, Siegel ER, Stack BC Jr. Is bisphosphonate-related osteonecrosis of the jaw an infection? A histological and microbiological ten-year summary. *Int J Dent* 2014;2014:452737.
  36. Mücke T, Koschinski J, Deppe H, Wagenpfeil S, Pautke C, Mitchell DA, et al. Outcome of treatment and parameters influencing recurrence in patients with bisphosphonate-related osteonecrosis of the jaws. *J Cancer Res Clin Oncol* 2011;137(5):907-13.
  37. Kunchur R, Need A, Hughes T, Goss A. Clinical investigation of C-terminal cross-linking telopeptide test in prevention and management of bisphosphonate-associated osteonecrosis of the jaws. *J Oral Maxillofac Surg* 2009;67(6):1167-73.
  38. Marx RE, Cillo JE Jr, Ulloa JJ. Oral bisphosphonate-induced osteonecrosis: risk factors, prediction of risk using serum CTX testing, prevention, and treatment. *J Oral Maxillofac Surg* 2007;65(12):2397-410.
  39. Awad ME, Sun C, Jernigan J, Elsalanty M. Serum C-terminal cross-linking telopeptide level as a predictive biomarker of osteonecrosis after dentoalveolar surgery in patients receiving bisphosphonate therapy: Systematic review and meta-analysis. *J Am Dent Assoc* 2019;150(8):664-675.e8.
  40. Kim YH, Lee HK, Song SI, Lee JK. Drug holiday as a prognostic factor of medication-related osteonecrosis of the jaw. *J Korean Assoc Oral Maxillofac Surg* 2014;40(5):206-10.
  41. Wutzl A, Pohl S, Sulzbacher I, Seemann R, Lauer G, Ewers R, et al. Factors influencing surgical treatment of bisphosphonate-related osteonecrosis of the jaws. *Head Neck*. 2012;34(2):194-200.
  42. Drake MT, Clarke BL, Khosla S. Bisphosphonates: mechanism of action and role in clinical practice. *Mayo Clin Proc* 2008;83(9):1032-45.

Received: 21 04 2022

Accepted for publishing: 27 12 2022