

Dynamical changes of occlusion and articulation during treatment of mandibular angle fractures*

Ausra Baltrusaityte, Algimantas Surna, Gaivile Pileicikiene, Ricardas Kubilius, Alvydas Gleiznys, Marijus Baltrusaitis

SUMMARY

Outcomes of mandibular fractures were stated as frequent reason of temporomandibular joint dysfunctions. The objective of this study was to evaluate dynamical changes of occlusion and articulation during treatment of mandibular angle fractures. 12 subjects with mandibular angle fractures underwent analysis of occlusion and articulation in all stages of healing. Findings of investigations were presented in Posselt's and intercondylar axis diagrams, occlusiograms and relative force vs. time graphs. Comparison of results in first day, 1, 3 and 6 months after trauma showed that despite typical process of fragments healing and good fixation but with insufficiently balanced occlusion and posttraumatic discoordination of muscle activity first signs of TMJ articular discs dysfunction were found. Our results confirm the concept that early rehabilitation of mandibular function and occlusion are essential to prevent developing functional disorders of TMJ.

Key words: mandibular fractures, occlusion, articulation, rehabilitation.

INTRODUCTION

Injuries of stomatognathic system, their course and sequences have significant influence on life quality, psychological and esthetical conditions of traumatized persons. Facial traumas amount 3.2–8% of all injuries (1-3). Mandibular fractures (MF) take 79.7% among facial traumas (3, 4). In 20–30% cases fractures occur in mandibular angle region (5). Majority of persons who experienced MF are young people: 20-29 years old persons make 36.3%, 30-39 years old – 25.9 % of all cases (2, 3, 6-8). According to statistics, there are annually around 500 patients with MF hospitalized in Department of Maxillofacial Surgery, Lithuanian University of Health Sciences, Kaunas, Lithuania (9). Appropriate treatment and rehabilitation of patients with MF are very important from a

social and economical viewpoint. Most studies were intended for pathology of temporomandibular joint (TMJ) in result of fractures of mandibular condyle (10-13). Only several studies emphasized that former fractures of mandibular body may had become the reason of TMJ's dysfunctions (14, 15). Alterations of occlusion and articulation during healing and rehabilitation of MF were investigated episodically. Well-timed, purposive and integrated treatment of MF is relevant and efficient on purpose to avoid possible dysfunctions of TMJ and has critical influence on further rehabilitation and its results (16). Course of MF's rehabilitation should be preventive and adapted to biological processes that happen during healing of bone, such as formation of bony scar, concrecence of bony tissue, functional changeover of bony scar. Optimal treatment of MF should run in following course: accurate reposition of fragments, stable maxillomandibular fixation (MMF), secured function, timely removal of MMF, stage-by-stage equilibration of occlusion and individually composed program of rehabilitation to re-establish function of masticatory muscles and coordination of TMJ's movements.

The purpose of this investigation was to evaluate dynamical changes of occlusion and articulation during treatment of mandibular angle fractures and

¹Clinical Department of Dental and Maxillar Orthopaedics, Lithuanian University of Health Sciences, Kaunas, Lithuania

²Department of Maxillofacial Surgery, Lithuanian University of Health Sciences, Kaunas, Lithuania

³Faculty of Informatics, Kaunas University of Technology, Kaunas, Lithuania

*Ausra Baltrusaityte*¹ – D.D.S., assist. prof.
*Algimantas Surna*¹ – D.D.S., PhD, assoc. prof.
*Gaivile Pileicikiene*¹ – D.D.S., PhD, lecturer,
*Ricardas Kubilius*² – D.D.S., dr. hab. med., prof.
*Alvydas Gleiznys*¹ – D.D.S., PhD, assoc. prof.
*Marijus Baltrusaitis*³ – IT specialist

Address correspondence to Ausra Baltrusaityte, Clinical Department of Dental and Maxillar Orthopaedics, Sukileliu 51, LT-50106, Kaunas, Lithuania.
 E-mail address: ausra.baltrusaityte@gmail.com

*A color version of this article can be found at <http://www.sbdmj.com/131/131-2.html>.

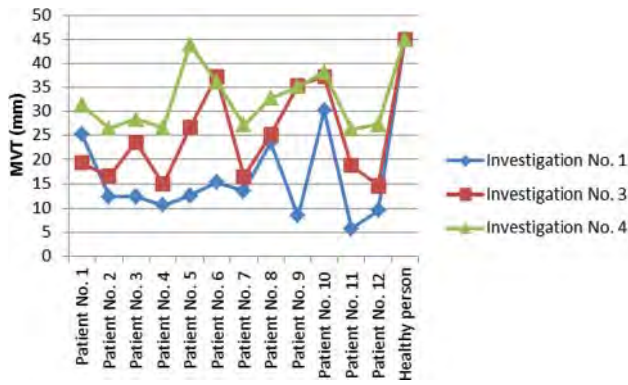


Fig. 1. Maximal vertical track (MVT) of mandibular incisors

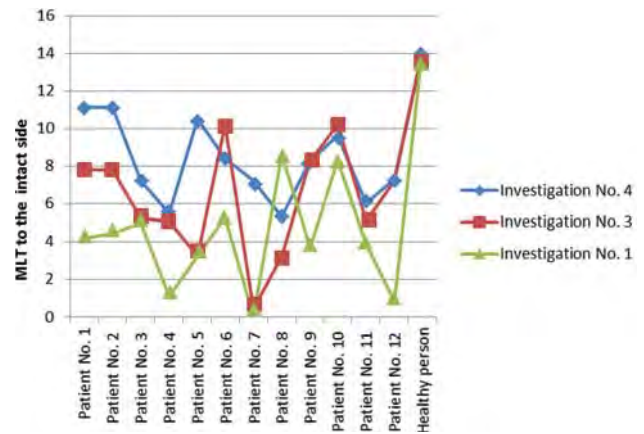


Fig. 2. Maximal lateral track (MLT) of mandibular incisors to the intact side

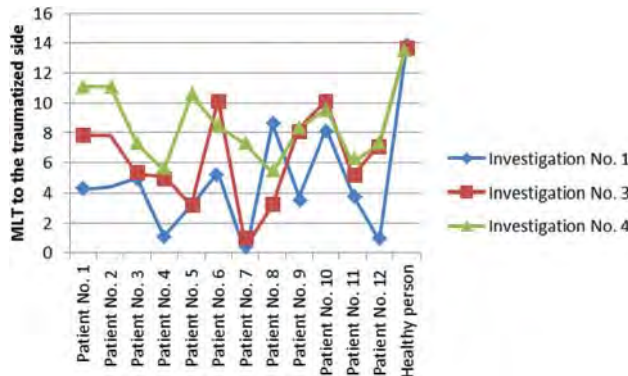


Fig. 3. Maximal lateral track (MLT) of mandibular incisors to the injured side

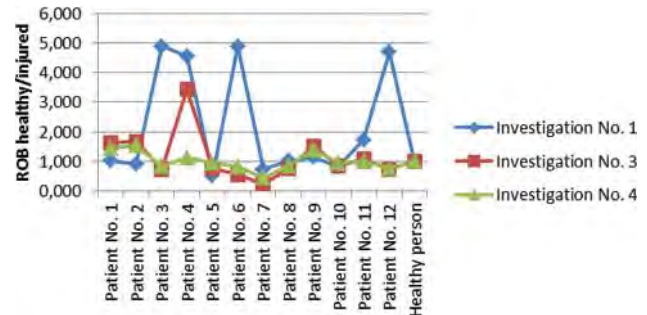


Fig. 4. Relation of occlusal balance (ROB) between the intact and injured sides

review requirement of rehabilitation methods and their corrections considering course of MF treatment.

MATERIALS AND METHODS

Subjects

From patients hospitalized in Department of Maxillofacial Surgery, Lithuanian University of

Health Sciences, Kaunas, Lithuania, with diagnosis of unilateral mandibular angle fracture, there were 12 subjects (all of them males) selected for this investigation. The age of subjects ranged from 19 to 45 years old. Maxillomandibular fixation (MMF) was applied to all of the subjects. Alterations of occlusion and articulation were analyzed in all stages of MF’s healing (17): acute stage – the first day after

Table. Time of investigations during the stages of MF’s healing

Patient’s No.	Location of the fracture	Time after injury (days)					
		Investigation No. 1	Immobilisation	Investigation No. 2	Removal of the MMF	Investigation No. 3	Investigation No. 4
1.	Left side angle, without dislocation	2	3	30	37	88	170
2.	Right side angle, without dislocation	1	1	29	36	90	172
3.	Left side angle, with dislocation	3	3	33	40	89	173
4.	Right side angle, without dislocation	1	1	31	38	85	168
5.	Right side angle, without dislocation	2	2	34	41	90	170
6.	Left side angle, with dislocation	3	3	35	42	92	172
7.	Left side angle, without dislocation	4	4	34	41	90	176
8.	Left side angle, with dislocation	7	7	37	44	96	180
9.	Left side angle, with dislocation	2	2	30	37	89	170
10.	Left side angle, without dislocation	3	3	31	38	85	171
11.	Right side angle, with dislocation	1	1	29	36	89	169
12.	Left side angle, without dislocation	1	1	30	37	88	168

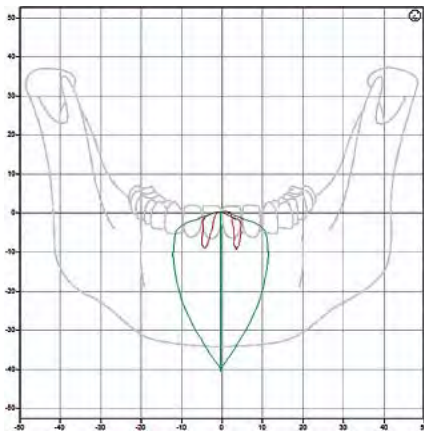


Fig. 5. Posselt's diagrams in the frontal plane: of a healthy subject (green) and patient J.G., first day after injury (brown)

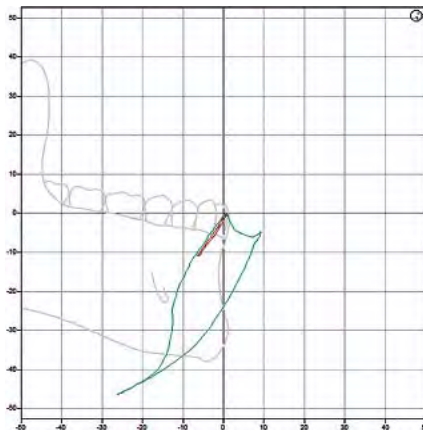


Fig. 6. Posselt's diagrams in the sagittal plane: of a healthy subject (green) and patient J.G., first day after injury (brown)

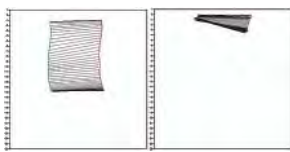


Fig. 7. Intercondylar axis diagrams during opening: of a healthy subject (left) and patient J.G., first day after injury (right)

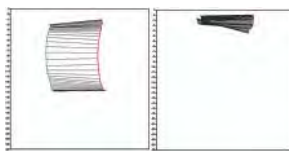


Fig. 8. Intercondylar axis diagrams during closing: of a healthy subject (left) and patient J.G., first day after injury (right)

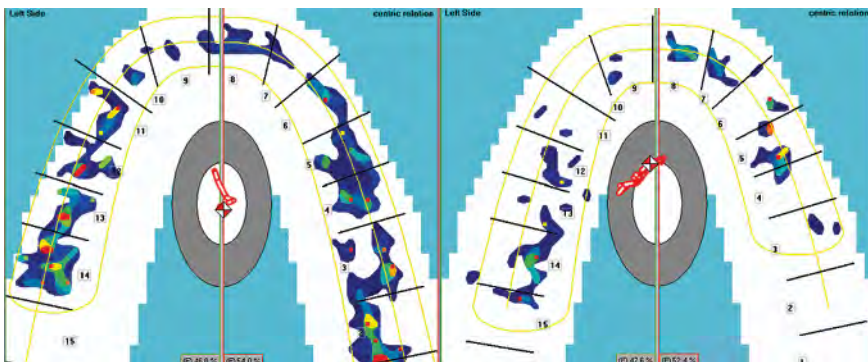


Fig. 9. Occlusiograms of a healthy subject with balanced occlusion (left) and patient J.G., first day after injury (right)

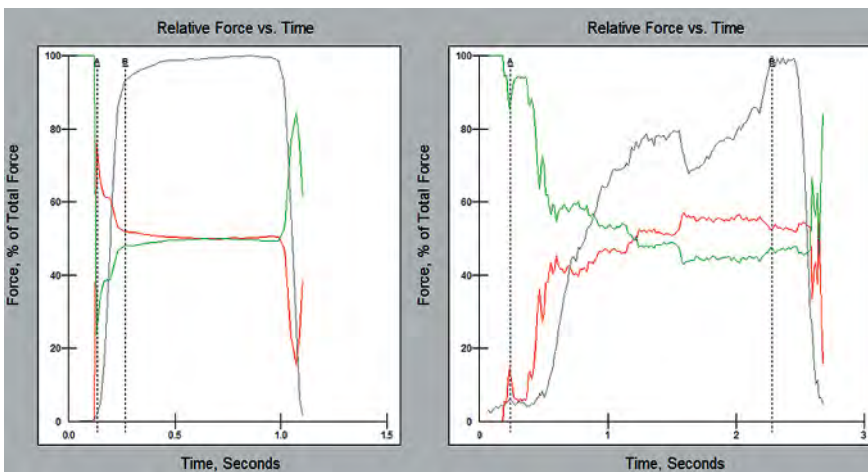


Fig. 10. Physical parameters of occlusion: balanced occlusion of a healthy subject (left) and patient J.G., first day after injury (right)

injury, before MMF; 1 month after injury, in stage of bony scar maturation and secondary changeover, after removal of MMF; 3 months after injury and 6 months after injury (Table).

Articulation analysis

Articulation of the mandible was analyzed using ZEBRIS ultrasound system (Jaw Motion Analyzer, Zebris Medical GmbH, Isny, Germany). Following parameters were estimated: amplitudes of spatial pathways of condyles and incisal points, equivalence and rate of the movements. Results of analysis are presented in Posselt's diagrams in two planes: frontal and sagittal; accuracy of movement analysis is $\pm 0.1\text{mm}$ (18). The Posselt's diagrams represent the movement limits of the incisal point in maximum sagittal and frontal jaw movements. In addition, the movement of the incisal point is shown in the opening and closing movements. Pathways of the intercondylar axis during opening and closing movements are displayed in the axis diagrams where green line indicates pathway of the right condyle, red line – of the left condyle.

Occlusal analysis

Dynamic occlusion analysis was performed with T-Scan analyzer (Tekscan, Inc., Boston, MA, USA) using two modes of time and force analysis, there were evaluated locations of occlusal contacts, their active areas, shapes, relative forces, total centre of occlusal forces and alternations of bite force balance in time (19-22). Findings of analysis are visualized in occlusiograms and relative force vs. time graphs of physical parameters of occlusal contacts, where green lines indicate relative bite force rates of left side and red lines – of a right side; meanwhile resultant of a bite force is shown as a grey line.

RESULTS

Investigations of 12 traumatized persons healing and functional regeneration processes did not find any significant differences between cases as well as complications during conventional rehabilitation (Figures 1-3). Regulation of occlusal balance for the traumatized persons is multifactorial process which is reliant on structural integrity as well as on character of neuroregulatory adaptation of the subject. Graphic analysis of the occlusal balance regulation did not show any significant directional tendency of the process (Figure 4).

After evaluating the tendencies of alterations in occlusion and articulation, we present for consideration a standard clinical case of patient J. G. (45 years of age) with unilateral (on the right side) mandibular angle fracture, which completely describes essence of the problem.

Findings of the first day after injury

Occlusion and articulation of the patient J. G. were investigated in acute stage without anesthesia, before MMF. It was found strong restriction of mandibular movements with deviation to the traumatized (right) side during jaw opening and lateral movements.

Findings of analysis visualized in Posselt's diagrams indicated significant fragmentation and small amplitude of mandibular movements in frontal plane (Figure 5) – up to 9 mm, in comparison with 40 mm for the healthy person. In sagittal plane were determined restricted movements (up to 10 mm) without protrusion (Figure 6). Pathway of the intercondylar axis in the right side was minimal – restricted to 1 mm and uneven with deviation to the traumatized side, whereas movement amplitude of the condyle in the intact side was found better (up to 3 mm) but still was far from norm (15 mm) (Figures 7 and 8). Occlusal analysis showed disbalance of occlusal contacts with deviation of total centre of occlusal forces to the left side (Figure 9). There were determined unstable physical parameters of occlusal con-

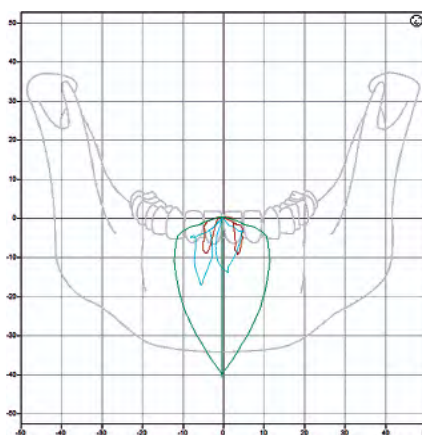


Fig. 11. Posselt's diagrams in the frontal plane: of a healthy subject (green) and patient J.G., first day (brown) and 1 month (blue) after injury

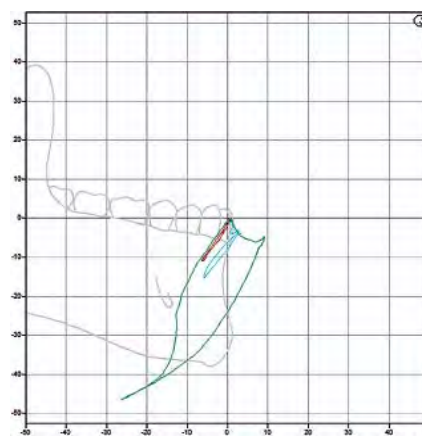


Fig. 12. Posselt's diagrams in the sagittal plane: of a healthy subject (green) and patient J.G., first day (brown) and 1 month (blue) after injury

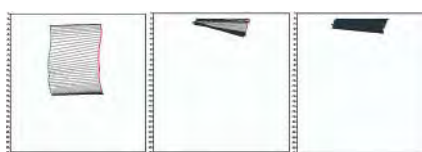


Fig. 13. Intercondylar axis diagrams during opening: of a healthy subject (left) and patient J.G., first day (center) and 1 month (right) after injury

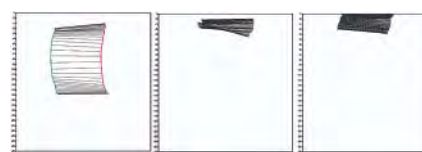


Fig. 14. Intercondylar axis diagrams during closing: of a healthy subject (left) and patient J.G., first day (center) and 1 month (right) after injury

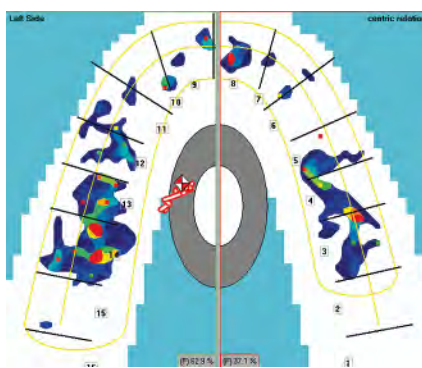


Fig. 15. Occlusiogram of patient J.G. 1 month after injury

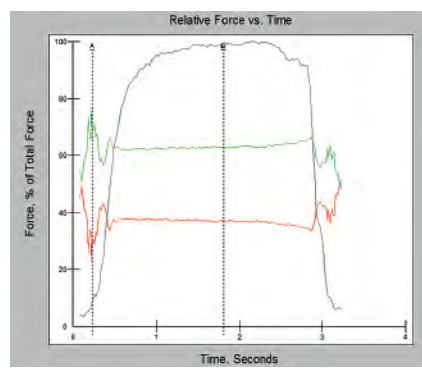


Fig. 16. Physical parameters of occlusion of patient J.G. 1 month after injury

tacts (Figure 10): resultant of bite forces achieved the maximum only in the end of clenching phase; distance between lines A and B in relative force vs. time graph was more than 0.2 s (in balanced occlusion it should be ≤ 0.2 s) (20). All above mentioned findings indicate significant disbalance of occlusion.

Findings 1 month after injury

One month after injury, after removal of MMF, occlusion and articulation of patient J.G. were analyzed. In result of healing of bony fragments and post-traumatic pain reduction amplitude of mandibular movements increased to 16 mm as well as their symmetry. Fragmentation of movement in frontal plane remained, but it was defined restriction of condylar movement in the intact side,

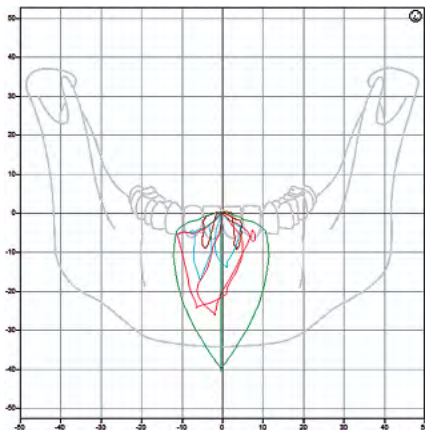


Fig. 17. Posselt's diagrams in the frontal plane: of a healthy subject (green) and patient J.G., first day (brown), 1 month (blue) and 3 months (red) after injury

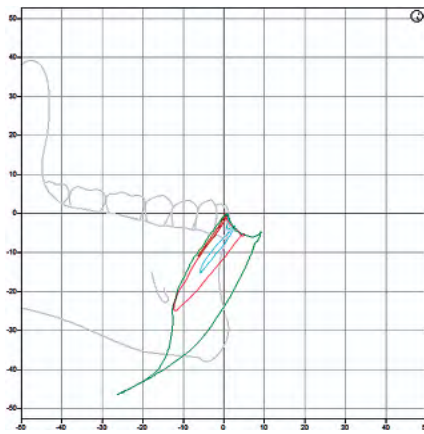


Fig. 18. Posselt's diagrams in the sagittal plane: of a healthy subject (green) and patient J.G., first day (brown), 1 month (blue) and 3 months (red) after injury




Fig. 19. Intercondylar axis diagrams during opening: of a healthy subject (left) and patient J.G., first day (center), 1 month (right) and 3 months (below) after injury




Fig. 20. Intercondylar axis diagrams during closing: of a healthy subject (left) and patient J.G., first day (center), 1 month (right) and 3 months (below) after injury

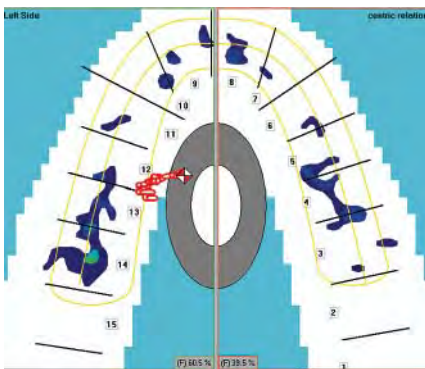


Fig. 21. Occlusiogram of patient J.G. 3 months after injury

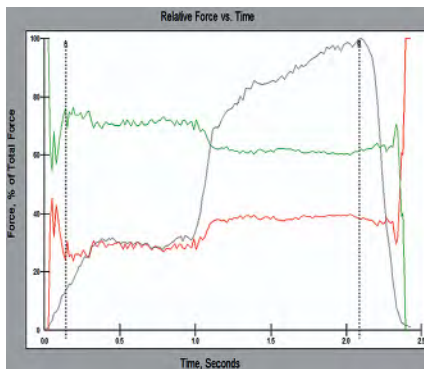


Fig. 22. Physical parameters of occlusion of patient J.G. 3 months after injury

possibly as a result of takeover of the function of mandibular position stabilization (Figure 11). In sagittal plane it was defined slight protrusive slip up to 3 mm (Figure 12). Pathways of the intercondylar axes in diagrams defined as still asymmetric, but in the traumatized side their amplitude increased to 2 mm, while in the intact side remained restricted to 3 mm, therefore during opening mandible still deviated to the injured side (Figure 13). During closing mandibular movements were found closer to norm,

this may be explained by character of the retrusive movement which is much easier and less painful than the protrusive one (Figure 14). Balance of bite force resultants 1 month after trauma did not show essential positive changes: occlusal contacts began and staid stronger in the intact side, although slight contacts were noticed in the side of fracture (Figure 15). Comparable lines of occlusal forces in the right and left sides still didn't touch, although resultant of bite forces was more equal, but time till maximum bite force staid longer than 0.2 s (Figure 16).

Findings 3 months after injury

Analysis of articulation performed for patient J.G three months after his trauma showed that amplitudes of mandibular movements were closer to normal if compared with previous results, but their spatial character indicated progress of TMJ dysfunction. In frontal plane of Posselt's diagram amplitudes of mandibular movements increased to 25 mm, but remained asymmetric and uneven (Figure 17). In sagittal plane there was found stronger protrusive slip up to 5 mm (Figure 18). Pathways of the intercondylar axes in diagrams were still asymmetric but their amplitudes increased: up to 6 mm in the right side and to 8 mm in the left (Figure 19). Diagrams of intercondylar axes during opening and closing indicated bilateral reversible dislocation of articular discs (red arrows in Figures 15 and 20). There we no physical or mechanical obstacles for spatial orientation of articular discs, so their might become uncoordinated in result of dysfunction of muscles responsible for articulation. Examination of occlusion with T-Scan analyzer showed that process of adaptation in stomatognathic system has begun, but some signs of unbalanced occlusion remained – occlusiogram indicated that balance of bite force resultants was still in the left side (Figure 21). In the graph of physical parameters of occlusal contacts comparable lines of occlusal forces in the

right and left sides still didn't touch whereas time till maximum bite force staid longer than 0.2 s (Figure 22). These findings indicated that 3 months after trauma there were no essential positive changes in patient's occlusion.

Findings 6 months after injury

Examination of articulation and occlusion six months after injury gave results almost identical to those obtained in three months after trauma. Fragmentation of mandibular movements remained as well as their deviations to the injured (right) side (Figures 23-26). Signs of occlusal disbalance persisted (Figures 27, 28). Despite successful biological healing of fractured bone, functional rehabilitation was still far from acceptable level. Findings of our investigations showed the progress of TMJ's dysfunction manifested by reversible dislocation of articular disc during both opening and closing movements of the mandible (arrows in Figures 25 and 26).

DISCUSSION

It has been reported that all the patients with MF had various signs of anatomical and functional disorders in TMJ and soft tissues of masticatory system caused by two interdependent factors: (1) mechanical injuries, related with the reason of trauma; (2) alterations in the masticatory system produced by action of masticatory muscles i.e. dislocations of bony fragments (23). The stronger force was reason of trauma, the heavier were dislocations and injuries of soft tissues (24, 25). All the methods of MF treatment were classified to conservative (symptomatic and functional) and active (immobilizing of fragments by various techniques of osteosynthesis) treatment (25-28). Conservative treatment of MF includes maxillomandibular fixation and physiotherapy. Though in many cases after conservative treatment were established developed disturbances of mandibular movements, occlusion and dysfunc-

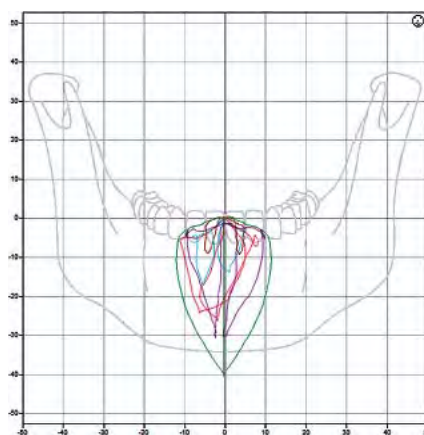


Fig. 23. Posselt's diagrams in the frontal plane: of a healthy subject (green) and patient J.G., first day (brown), 1 month (blue) 3 months (red) and 6 months (purple) after injury

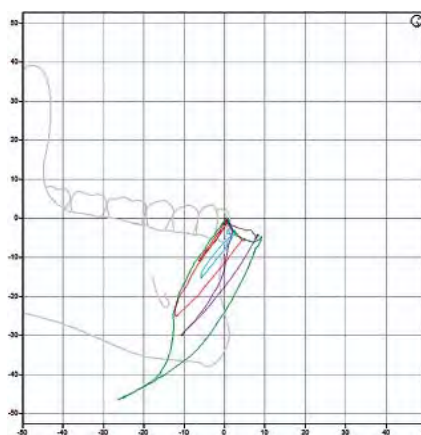


Fig. 24. Posselt's diagrams in the sagittal plane: of a healthy subject (green) and patient J.G., first day (brown), 1 month (blue) 3 months (red) and 6 months (purple) after injury




Fig. 25. Intercondylar axis diagrams during opening: of a healthy subject (left) and patient J.G., first day (center), 1 month (right), 3 months (below left) and 6 months (below right) after injury




Fig. 26. Intercondylar axis diagrams during closing: of a healthy subject (left) and patient J.G., first day (center), 1 month (right), 3 months (below left) and 6 months (below right) after injury

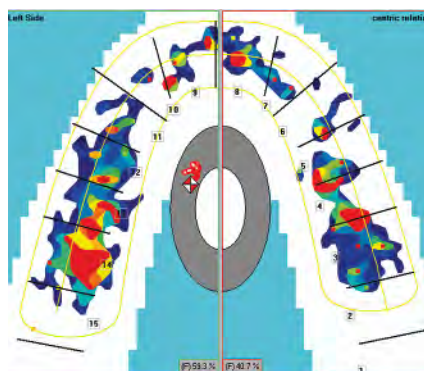


Fig. 27. Occlusiogram of patient J.G. 6 months after injury

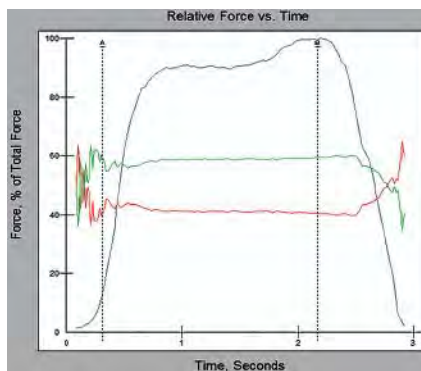


Fig. 28. Physical parameters of occlusion of patient J.G. 6 months after injury

tion of TMJ (29, 30). Alterations of soft tissues surrounding the TMJ were stated as one of the possible reasons of TMJ dysfunction (31). Some authors reported that in result of MF geometrical structure of masticatory system was affected, nutrition of TMJ and surrounding tissues was disturbed, response of injured tissues to trauma was manifested, all of above mentioned elements resulted in contractures of masticatory muscles, progressive dysfunction and arthritis of TMJ with myogenic origin (32). Other-

wise other studies about conservative treatment of MF showed that due to insufficiently accurate immobilization after trauma “new bite” was developed and as a result of adapted dynamical stereotype of masticatory movements and new occlusion, conditions for development of TMJ dysfunction with neuroreflectoric origin were formed (33, 34). It was reported that in period 3 to 6 months after MF adaptation to the “new bite” are in process, moreover, dysfunctional alterations in TMJ may be reversible as dysfunction of masticatory muscles is of inflammatory character (which afterwards changes over to contractive type) therefore this period was described as very important in development of chronic disorders of TMJ and masticatory muscles functions (35). Results of our study confirmed this. However, if adaptive process is well developed, disorders of posttraumatic period may be not manifested after 6 months anymore. If injuries are harder and process of adaptation is disturbed then stressful reaction of organism proceeds, disorders of masticatory muscles coordination (with neuroreflectoric origin) start and in result dysfunction of TMJ develops (36). During rehabilitation process of our investigated 12 subjects complete regeneration of function did not occur. Contrarily, in default of purposeful and sufficiently efficient kinezitherapical treatment dysfunctions of TMJ of different degree were diagnosed for all the subjects in our study. Posttraumatic alterations in masticatory muscles, TMJ and surrounding soft tissues depend on location of MF and time after trauma when treatment was started (37). In study about healing of experimental fractures of rabbits mandibles was found that when dislocation of fragments was marked, in only 3 months after trauma destructive and dysfunctional alterations in TMJ (particularly in the injured side) were observed; and in some cases even fibratization of articular capsule was found (38). The same study reported that when MF was located in the centre of mandible and without dislo-

cation, 3 months after trauma there were not found any morphological and morphofunctional changes in masticatory muscles and TMJ structures, however if there were marked dislocation of fragments and big affections of masticatory muscles, accretions in the muscles were found whereas destructive and dystrophic changes of TMJ structures were noticed (38). Our study confirmed abovementioned findings: 3 months after trauma, despite typical process of fragments healing and good fixation but with insufficiently balanced occlusion and posttraumatic discoordination of muscle activity, first signs of TMJ articular discs dysfunction were found. Consequently in rehabilitation after MF, except perfect immobilization, sufficient attention to restoration of maximum possible balance of occlusion and coordination of masticatory muscles by kinezitherapical means should be paid. It was reported that after active treatment (osteosynthesis) of MF, during period of rehabilitation, exercise of masticatory muscles started next day after immobilization in 3 weeks gave much better electromyography results if compared to passive healing (39).

CONCLUSIONS

Investigations of all the 12 clinical cases analyzed in our study supported statements in the reviewed literature that appropriate and well-timed fixation of bony fragments is topical in treatment of MF. Despite it, during process of trauma healing dysfunction of TMJ often shows up as outcome of complex affections. Timely evaluation of patient's occlusion, early correction and proper orthopaedic treatment are essential factors for stimulation of healing and rehabilitation after MF. Early rehabilitation of mandibular function and occlusion stimulates coordinated activity of masticatory muscles and consequently helps to compensate developing functional disorders of TMJ.

REFERENCES

1. Lurje TM, Malyshev V.A. [Organization of care to the trauma maxillofacial area]. Moskva; 1983. Rus.
2. Aleksandrov NM, Arzancev PZ, Vichriev ADS. [Injuries to the maxillofacial area]. Moskva; 1996. Rus.
3. Bernadskij JI. [Trauma and reconstructive surgery of maxillofacial area]. Kijev; 1999. Rus.
4. vanHove A, Lolom P, Sapanet M, Descrozailles JM. [Mandibular fractures. Retrospective study of the experience of the department of maxillo-facial surgery and stomatology of the university of poitiers medical center from 1978 to 1997] *Rev Stomatol Chir Maxillofac* 2000;101: 309-18. Fre.
5. Hendler B: Maxillofacial Trauma. In: Rosen P, ed. *Emergency Medicine: concepts and clinical practice*. Mosby: Year Book; 1998. p. 1093-103.
6. Zix JA, Schaller B, Lieger O, Saulacic N, Thorén H, Iizuka T. Incidence, aetiology and pattern of mandibular fractures in central Switzerland. *Swiss Med Wkly*. 2011; May 27:141
7. Cabrini Gabrielli MA, Real Gabrielli MF, Marcantonio E, Hochuli-Vieira E. Fixation of Mandibular fractures with 2.0-mm miniplates: review of 191 cases. *J Oral Maxillofac Surg* 2003; 61: 430-6.
8. Ogundare BO, Bonnick A, Bayley N. Pattern of mandibular fractures in an urban major trauma center. *J Oral Maxillofac Surg* 2003;61:713-8.
9. Lukošūnas A., Kubilius R., Sabalys G., Keizeris T., Sakavičius D. An analysis of etiological factors for

- traumatic mandibular osteomyelitis *Medicina (Kaunas)* 2011;47:380-5.
10. Carneiro S, Vasconcelos BC, Caldas JrA, Leal J, Frazão M. Treatment of condylar fractures : a retrospective cohort study. *Med Oral Patol Oral Cir Bucal* 2008;13:589-94.
 11. Wilkes C.H. International derangement of the temporomandibular joint. *Otolaringol. Head Neck Surg.* 1989;115:469-77.
 12. Sysoliatin PG, Il'in AA, Dergilev AP. [Classification of diseases and injuries of the temporomandibular joint]. Moskva; 2001. Rus.
 13. Silvennoinen U, Raustia A. M., Lindqvist Ch., Olkarinen K. Occlusal and temporomandibular joint disorders in patients with unilateral condylar fracture: A prospective one-year study *International J Oral Maxillofac Surg* 1998;27:280-5.
 14. Zachariades N, Mezitis M, Mourouzis C, Papadakis D, Spanou A. Fractures of the mandibular condyle: a review of 466 cases. Literature review, reflections on treatment and proposals. *J Craniomaxillofac Surg* 2006;34:421-32.
 15. Antonik MM, Kalinin IuA. [The use of instrumental diagnostics registered head displacement jaw as an important element of complex diagnosis of muscular and joint dysfunction in patients with abnormal occlusion]. *Rossiiskii stomatologicheskii zhurnal*, 2011;3:15-6. Rus.
 16. Bagautdinova VI, Agapov VS. [Effect of chronic musculo-articular disorders, previous injury, for a fracture of the mandible]. *Institut Stomatologii* (Sankt Peterburg); 2002;4:24-7. Rus.
 17. Urazalin ZB. [Issues of improving medical care for patients with fractures mandible (clinical and experimental studies) [dissertation].] Moskva; 1985. Rus.
 18. Best N. Untersuchungen zur Reliabilität und Validität der dreidimensionalen. Kiefergelenkfunktionsanalyse mittels Zebris WinJaw-System [dissertation]. Jena; 2010.
 19. Qadeer S, Kerstein R, Kim RJY, Huh JB, Shin SW. Relationship between articulation paper mark size and percentage of force measured with computerized occlusal analysis. *J Adv Prosthodont* 2012;4:7-12.
 20. Garrido Garcia VC, Garcia Cartagena A, Gonzales Sequeros O. Evaluation of occlusal contacts in maximum intercuspation using the T-Scan system. *J Oral Rehabil* 1997; 24:899-903.
 21. Olivieri F, Kang K, Hirayama H, Mannes WL. New method for analyzing complete denture occlusion using the center of force concept: A clinical report. *J Prosth Dent* 1998;80:519-23.
 22. Suda A, Machida N, Momose M, Yamaki M, Seki Y, Yoshie H, et al. A multiparametric analysis of occlusal and periodontal jaw reflex characteristics in adult skeletal mandibular protrusion before and after orthognathic surgery. *J Oral Rehabil* 1999;26:686-90.
 23. Bagautdinova VI, Agapov VS. [Results of treatment of patients with mandibular fractures and underlying chronic muscle and joint dysfunction]. *Institut Stomatologii* (Sankt Peterburg) 2003;2:19-23. Rus.
 24. Vernadskii IuI. [Traumatology and reconstructive surgery of maxillofacial area]. Kiev; 1985. Rus.
 25. Kabakov BD, Malyshev VL. [Fractures of jaws]. Moskva; 1981. Rus.
 26. Aleksandrov NM, Arzancev PZ, editor. [Injuries to the maxillofacial area]. Moskva; 1986. Rus.
 27. Aleksandrov NM, editor. [Clinical operative maxillofacial surgery]. Leningrad; 1985. Rus.
 28. Lurje TM. [Trauma of maxillofacial area]. Moskva; 1977. Rus.
 29. Joos U, Kleinheinz J. Therapy of condylar neck fractures. *Int J Oral Maxillofac Surg* 1998;27:247-54.
 30. Rubens BC, Stoelinga PJ, Weaver TJ, Blijdorp PA. Management of malunited mandibular condylar fractures. *Int J Oral Maxillofac Surg* 1990;19:22-5.
 31. Shaichutdinov IF. [Biomechanical patterns of stress distribution in the temporomandibular joint and their importance to clinical prosthodontics][dissertation]. Kemerovo; 1990. Rus.
 32. Petrosov IuA. [Orthopaedic treatment of dysfunctional syndromes, arthritis and arthrosis of the temporomandibular joint][dissertation]. Krasnodar; 1982. Rus.
 33. Luglio A. [Post-traumatic myo-arthropathy of the mandibular joint. Report of a case]. *Minerva Stomatol* 1995;44:485-8. Ita.
 34. Pullinger A.G., Seligman D.A. Trauma history in diagnostic groups of temporomandibular disorders. *Oral Surg* 1991;71:529-34.
 35. Lebedenko II., Arutiunov SD, Antonik MM. [Instrumental functional diagnostics of dentition]. Moskva; 2010. Rus.
 36. Egorov PM, Karapetian IS. [Painful dysfunction of the temporomandibular joint]. Moskva; 1986. Rus.
 37. Bagautdinova VI, Agapov VS. [Acute musculo-articular disorders in mandibular fractures of different location and methods of their correction]. *Stomatologija (Mosk)* 2003;82:39-43. Rus.
 38. Bagautdinova VI. [Impaired function of the temporomandibular joints in fractures of the lower jaw of various localization and correction methods (clinical and experimental studies)[summary of doctoral dissertation]. Moskva; 2004. Rus.
 39. Savelev AL. [Rationale for use therapeutic gymnastics in the early postoperative period in patients with mandibular fractures]. *Sovremennye problemy nauki i obrazovanija*. Rus. Available from: URL: <http://www.science-education.ru/pdf/2012/2/390.pdf>.

Received: 12 03 2012

Accepted for publishing: 22 03 2013