

The preservation of alveolar bone ridge during tooth extraction

Marius Kubilius, Ricardas Kubilius, Alvydas Gleiznys

SUMMARY

Objectives. The aims were to overview healing of extraction socket, recommendations for atraumatic tooth extraction, possibilities of post extraction socket bone and soft tissues preservation, augmentation.

Materials and Methods. A search was done in Pubmed on key words in English from 1962 to December 2011. Additionally, last decades different scientific publications, books from reference list were assessed for appropriate review if relevant.

Results and conclusions. There was made intraalveolar and extraalveolar postextractional socket healing overview. There was established the importance and effectiveness of atraumatic tooth extraction and subsequent postextractional socket augmentation in limited hard and soft tissue defects. There are many different methods, techniques, periods, materials in regard to the review. It is difficult to compare the data and to give the priority to one.

Key words: tooth extraction, grafting, socket, healing, ridge preservation.

INTRODUCTION

Nowadays tooth extraction becomes more important in complex odontological treatment. Three dimensional bones' and soft tissue parameters influence further treatment plan, results and long time prognosis. Tooth extraction inevitably has influence in bone resorption and changes in gingival contours. Further treatment may become more complex in using dental implants and common prosthetics. Marginal alveolar bone ridge protection has influence in achieving optimal functional, aesthetic prosthesis and orthodontic treatment results. There is increasing demand in lowering damage to soft and hard tissues around the tooth being extracted. Atraumatic tooth extraction and further protection of alveolus is important in preserving mentioned parameters. It is worth knowing and using contemporary treatment opportunities and methodological recommendations in everyday odontologist work. The represented paper gives op-

portunity to get acknowledge with summarized contemporary scientific publication results, methodologies and practical recommendations in preserving alveolar crest in tooth extraction (validity for atraumatic tooth extraction, operative methods, protection of alveolus after extractions, feasible post extraction fillers and complications, alternative treatment).

MATERIALS AND METHODS

A search was done in Pubmed for papers on key words („tooth extraction“, „grafting“, „socket“, „healing“, „ridge preservation“) from 1962 to December 2011. Titles were screened in English language. Additionally, last decades different scientific publications, books from reference list were assessed for appropriate review if relevant.

BONE RESORPTION

Alveolar bone ridge changes can occur for various reasons: ridge, pathological changes of chronic periodontitis, traumas (including the extraction of a tooth), developmental disorders (such as alveolar cleft), edentate of alveolar crest for long time, the mechanical effect of the alveolar crest, jawbones (upper or lower), tooth shape and others [1, 2]. According to the resorption the effect of factors can

*Department of oral and maxillofacial surgery, Kaunas Clinic, Lithuanian University of Health Science, Kaunas, Lithuania

*Marius Kubilius** – D.D.S.
*Ricardas Kubilius** – D.D.S., Dr. hab. med., professor
*Alvydas Gleiznys** – D.D.S., PhD, assoc. prof.

Address correspondence to Prof. Ricardas Kubilius, Department of Maxillofacial Surgery, Faculty of Odontology, Medical Academy, Lithuanian University of Health Sciences, Eiveniu str. 2, LT-50009 Kaunas, Lithuania.
E-mail address: ricardas.kubilius@kmuk.lt

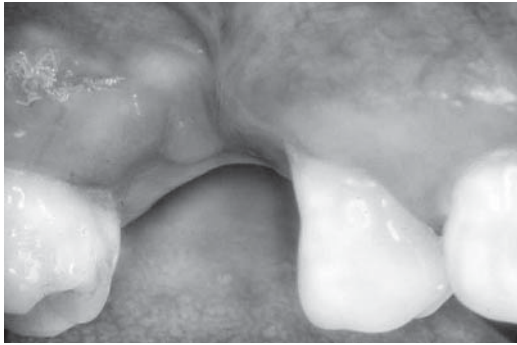


Fig. 1. Alveolar ridge defect after tooth extraction

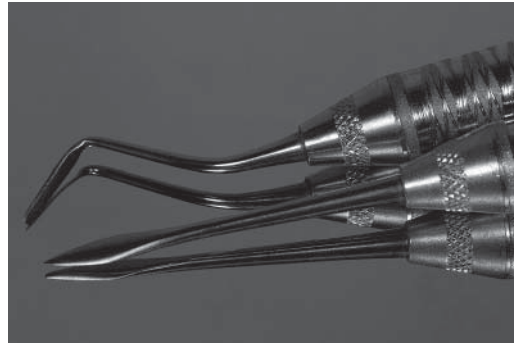


Fig. 2. Periostomes

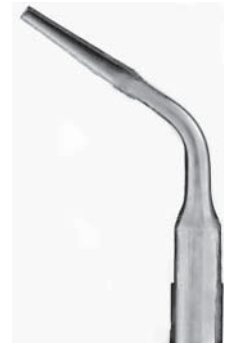

Fig. 3. Piezo ultrasonic tip

be divided into: anatomical, prosthetic, functional, and metabolic [3, 4].

INTRAALVEOLAR AND EXTRAALVEOLAR CHANGES AFTER TOOTH EXTRACTION

Changes of alveolar bone ridge after a tooth extraction are inevitable [5, 6]. It is a natural process where the models have been documented while studying animals and humans. The size of the alveolus affects the rate of healing – wider alveolar sockets require more time to bridge the defect. Bone height and width always undergo dimensional changes after extraction of a tooth. Bone does not regenerate above the horizontal level of alveolus crest, i.e. its height can not increase after the healing. After the healing event the crest of the residual ridge had shifted lingually when compared with the original position of the teeth before extraction and from the lateral aspect, the residual ridge often forms a concavity. The bigger facial wall damage (due to trauma or disease, etc.), the bigger deformation of the contours [7-9] (Fig. 1).

Intraalveolar changes

- When a tooth is removed the entire socket is filled by blood clot which is formed within 24 hours conclusively [10].
 - Within 2 to 3 days, the clot changes – it contracts and starts to break down as granulation tissue.
 - After 4 to 5 days the granulation tissue covers alveolar bone ridge usually, and the epithelium proliferates along the soft tissue periphery covering the granulation tissue.
 - By the end of 1 week, osteoid is evident at the apical portion (at the base) of the socket as uncalcified bone spicules; a vascular network is formed already, the young connective tissue is found.
 - After 3 weeks the alveolus is filled with connective tissue, while osteoid begins to mineralize, and the socket surface is covered with epithelium.

- After 6 weeks trabecular bone formation is observed. The bone deposition in the socket is seen well after two months.

- Bone deposition is decelerating after 4 to 6 months, but still will continue for a few months. The tissues are specializing to the varied functions [1, 11-13].

Extraalveolar changes

Anatomically buccal (labial, facial) alveolar bone ridge is thinner than lingual (palatal). Alveolar sockets are lined by cortical bone (alveolar bone proper or bundle bone, which radiologically appears as “lamina dura”) – the thin layer which forms a big part of fine coronal alveolar socket wall as well [14]. It is important that 1-2 mm of lamina dura forms alveolar bone ridge which is a part of periodontium (bundle bone of lingual wall is thinner). When a tooth is extracted – periodontium is destroyed so resorption of bundle bone follows [12]. In addition, resorption increases because of a mucoperiosteal flap elevation [15].

- After mucoperiosteal flap was elevated and a tooth extraction was done, in one week it is observed a significant increase in both quantity of osteoclasts on the inner and outer side of the alveolar walls.

- Two weeks later, osteoclasts were indeed present in the exposed area of the alveolar ridge [14], the young connective tissue and bundle bone replaced by immature bone intermittently.

- During the four-week period of monitoring a number of osteoclasts in the buccal site and alveolar bone ridge area and crest are seen, immature bone is replaced by trabecular one.

- In 8 weeks cortical bone covers alveolar socket. External alveolar walls and crest are still under resorption (the resorption of buccal surface is greater) [12].

Lately alveolar ridge changes during 12 months period after a tooth extraction were set:

- The width of the alveolar ridge was decreased by 50 per cent (approximately from a mean of 12 mm to 5.9 mm) [11, 13].

- The two-thirds width reduction of the alveolar ridge occurs during the first 3 months [5, 11].
- The alveolar walls loose vertical dimensions (0.7-1.8 mm) [13] (buccal site more than lingual).
- The bone level parameters (the height, the width) of the extracted tooth rather than the bone level of the adjacent teeth influencing the level to which the bone crest heals after extraction.
- Only slight changes in soft tissue height took place in the place of in the crestal part of the alveolar bone ridge [11].

During the first year after the extraction bone resorption was 10 times bigger over the subsequent.

A tooth loss, the change in function influence emerged edentulous alveolar bone lesions. It is found that the resorption of edentulous alveolar ridge in a case of removable dental prosthesis for wearing all life is four times faster in mandible [16]. The faster resorption is caused by strong bite force for the smaller surface of the lower jaw alveolar crest and peculiarities of bone structure. Edentulism for a long period results that only the thin part of alveolar ridge will cover basal jaw area.

THE TEETH EXTRACTION – POSSIBILITIES TO PRESERVATION OF SURROUNDING TISSUES

An atraumatic tooth extraction is very important to preservation of alveolar bone volume and surrounding soft tissues [17]. Optimal results are received when it is tried to perform the most atraumatic tooth extraction. The results are even better when additional alveolar preservation means are applied (bone replacements materials, dental implants, membranes) [18].

Prior to extracting the tooth, a full clinical and radiographic evaluation must be performed [2]. The tooth anatomical features are assessed. If the tooth crown was severely damaged or underwent various prosthodontical or endodontical treatments, it is breakable [19]. Additional difficulties may be caused by long and/or divergent, bulbous roots, root fusions, big curvedness, dimensional changes of periodontal ligament space or even dissolution (ankylosis), proximity of anatomically significant structures (maxillary sinus floor, mandibular canal).

Loosening of soft tissue attachment from the tooth

This procedure must be done with the minimal damage on soft tissues (gingiva) up to bone crest. Usually it is done by using elevators, luxators, but it is recommended to use scalpel or periosteal try-

ing to preserve interdental papillae. Periosteal elevators are used more and more widely (Fig. 2). Last-mentioned instruments can be used for tooth-gums range, periodontal fibres break-down, and bone removal from the tooth. Push-pull movements are performed to reduce tooth mechanical retention in the alveolar socket. Mucoperiosteal flap reflection must be avoided because of the reasons set above.

Tooth luxation and extraction

It is done using forceps, elevators avoiding marginal alveolar bone ridge damage [20]. To ease loosening (luxation) of a tooth some instruments can be used. Manufactures offer special piezo ultrasonic tips (Fig. 3) to break periodontal ligament (it is suggested to use only for the coronal third of extraction socket because of bleeding stopping effect influenced by cavitation). Even though there are extra instruments the extraction should be done with the forceps.

The tooth to be extracted often breaks (fraction of the roots about 44.76%, crown fraction about 34.21%, crown and root fracture about 1.32%) [21] (Fig. 4). It should be taken into account. It is recommended during atraumatic tooth extraction to section the tooth by applying straight or angled handpieces with fixed prolonged diamond or hard metal burrs cooling with saline abundantly. Size of the bur depends on the size of the tooth part to be sectioned [22]. These actions should be performed trying to avoid bone and soft tissue damages. Removal of dental hard tissues needs to be minimal but not the essential action for the atraumatic teeth extraction. Dividing can ease, without fracture to remove the tooth using other instruments. Some authors suggest removing entire crown and later section roots (if a tooth is multi-rooted), while others suggest sectioning of roots without entire crown removal. It is always recommended to remove sectioned, diverged tooth-roots separately. Non-loosened root is sectioned using a bur into several parts later extracted using elevators [22]. Ankylosed root part can be removed by using a small diamond bur preserving periodontal area tissues and later applying thin elevators. If there is noticed broken, loosen wide root canal for the extraction is enough the endodontic hand instruments of appropriate size can be used while they are implanted in to the canal. Minor loosen teeth fragments may be removed by washing them under saline stream or suction.

Broken root fragments must be extracted. Exceptionally root tip can be left according to present conception (especially there are close important anatomical structures, when extracting an

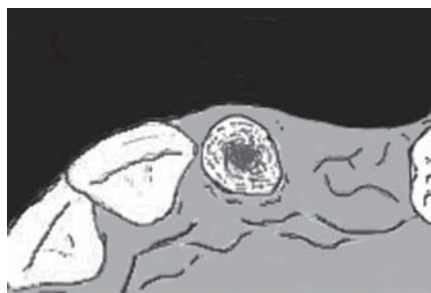

Fig. 4. Dental root Nr. 22 must be extracted due to poor conservative treatment prognosis

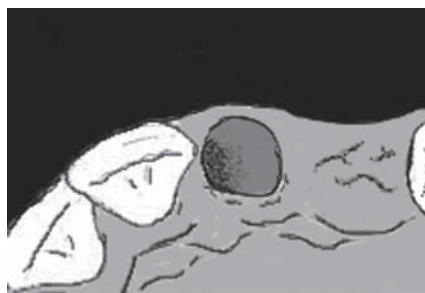

Fig. 5. Post-extraction socket

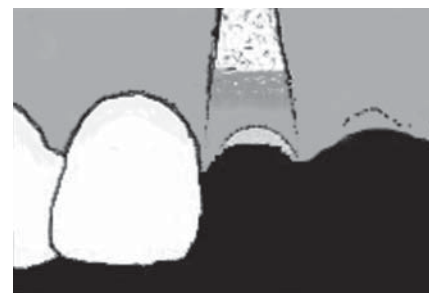

Fig. 6. Bone graft packed to the alveolar pit limit

impacted wisdom tooth or tooth when will not be inserted dental implant). This exception can be applied only if the assessment concludes that the risk of fragments retrieval is greater than non-removal from alveolar socket [22]. Absolute requirements: fragments of less than 4-5 mm deep in the bone, non-infected. It is believed that such fragments can be encapsulated or resorbed. Any left fragments or other infections causing debris can not be left in the space of implantation.

Cleaning of alveolar socket

After performed tooth extraction damaged tissues (marginal, periapical), remnants of fragments need to be removed thoroughly by selected size periapical curette or dental excavator. If healthy tissues are damaged, extraction socket is recovering more difficult. If insufficient bleeding is present, the apical bundle bone walls should be perforated in several places by round bur with a slow handpiece [2]. Insufficient haemorrhage of the socket causes more difficult healing.

Clot stabilization

After the tooth extraction (Fig. 5) clot has no mechanical stability in alveoli of high range. It can be washed out with water, damaged mechanically. It can complicate alveolar healing process. Stability of clot and dental crest improvement (especially when alveoli can be augmented) can be done with the following material combinations:

- a) surgical suture [20];
- b) collagen [13];
- c) polylactide/polyglycolide gel/sponge [23];
- d) isobutyl cyanoacrylate;
- e) temporary crown above the extraction socket.

As the alternative to surgical removal of tooth orthodontic extrusion can be applied [24-26].

Indications for the named treatment application:

- for the treatment of coronary-third of the tooth root and alveolar bone under gingival mar-

gin defects around the tooth, (e.g. for external root resorption, tooth decay), especially in aesthetically important zones;

- reconstruction of biological width when a tooth is affected during restoration;
- reduction of isolated periodontal pockets and bone defects;
- preservation of alveolar bone ridge or restoration before implantation;
- tooth extraction, when usual dental surgical removal is contraindicated (e.g. when applying chemotherapy);

- extrusion of traumatized or impacted teeth.

There are such disadvantages of the treatment:

- relatively long treatment (4-6 weeks for extrusion, and from 4 weeks to 6 months for retention period when implantation is going to be performed later);
- the need to wear orthodontic appliances, which for some patients may be aesthetic problem and complicate oral hygiene;
- soft tissues may need to be adjusted after treatment.

For the appliance of this treatment there is more than one contraindication, depending on the extrusion aim [24].

Marginal alveolar bone ridge volume preservation alternatives after a tooth extraction:

- autogenous tooth transplantation [27];
- orthodontic correction of dental arches [28];
- hard and soft tissue augmentation [29];
- dental implant placement (resorption inhibition in a long-term perspective) [11, 29].

Peak preservation of the alveolar bone ridge dimensions after tooth extraction using bone defect fillings and soft tissue grafts

Success of dental implant placement (especially anterior teeth region) is determined by fulfilled complex requirements. One of the most important is sufficient height and width of alveolar bone ridge. Another requirement of the same importance is

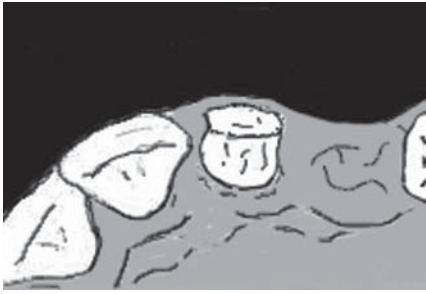

Fig. 7. Collagen plug placed over the bone graft

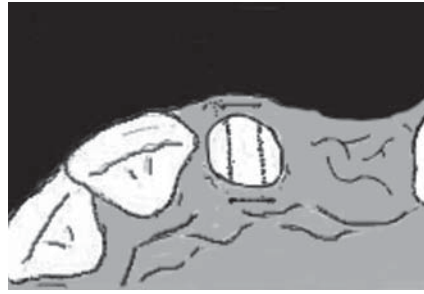

Fig. 8. Surgical suture stabilized collagen plug through soft tissues

adequate thickness of soft tissue covering the bone. Satisfactory parameters allow a specialist to place an implant in an ideal position in accordance with adjacent teeth. Because of above-mentioned extraalveolar and intraalveolar processes socket width and height changes are observed. Buccal bone surrounding the implant must be at least of 2 mm, so the vertical alveolar bone resorption would not progress. If after implantation buccal site thickness is less than 2 mm, vertical bone resorption is likely to occur [30, 31]. In addition, gingival biotype influences outlying outcomes of implantation as well [25]. There is a need to preserve or even increase the hard and soft tissue using a simpler, less damaging and costly interventions, reducing the number of visits [13]. These set requirements provide importance to preservation procedure of marginal alveolar bone ridge during a tooth extraction, which often reduce and sometimes eliminate the need for subsequent augmentation procedures [13, 25]. During immediate implantation, these procedures help to maintain the alveolar bone ridge and gingival anatomy. If there is a need of additional augmentation procedures before implant placement then preservation and augmentation procedures of extraction socket at the time of tooth removal is an important preparatory stage, which increases the success of the later augmentation.

Several studies were carried out to determine the changes of post-extraction site using different materials and tissues [12, 13, 15, 17, 23 32].

- Statistically significant benefit of to be resorbable and non-resorbable membranes was confirmed when using them as barrier and/or shape maintaining material [18, 32]. It preserves from soft tissues unwanted ingrowth.

- Materials for the guided bone regeneration (autogenous, allogenic, xenogenic and alloplastic biomaterials, polylactide/polyglycolide gel/sponge [33], collagen pads) maintain the volume of alveoli and do not allow deformation of the contours.

- Soft tissue grafts. They help to optimize bone and soft tissue healing and volume preser-

vation. There can be used free or pediculed flap, subepithelial or keratinized free autogenous gingival transplants [34]. Good results are obtained using allogenic membranes [35].

These materials have advantages and negative characteristics which need to be considered when choosing one or the other offered product.

Choice of bone-defect-fillings recommended in the literature depends on the planned time for augmentation [4]:

- *Short-term augmentation materials.*

For this purpose, autografts or allografts [36] are used. They can be used together with materials for average augmentation period, the ratio of 50:50 or 75:25. These are designed for 3-6 months. Autogenous bone is the most suitable material for bone grafting [26, 37], but requires second surgery and provides more morbidity to the patient. Autogenous bone is regarded as the gold standard grafting material. There are three forms of autografts: cortical, cancellous, corticocancellous. Limited studies are available for alveolar socket augmentation with autogenous bone [38]. The recent study states no advantage of fresh extraction socket augmentation with particulate autogenous bone chips [38]. There are several forms of allografts: fresh frozen, freeze-dried bone allograft (FDBA), demineralised freeze-dried bone (DFDBA) [39]. The first allograft is used rarely because of diseases transmission possibilities.

- *Materials for the average (transitional) augmentation period.*

Xenogenic bone grafts (e.g. anorganic bovine bone matrix) are intended for this purpose. They can be divided in two groups according to the graft bone preparation: low temperature with chemical extraction process and high temperature [39].

Coral-derived granules are natural source calcium carbonate derived from madreporic corals. During preparation process coral can be converted to different porosities hydroxylapatite (HA) granules with different resorption and bone formation rates [39].

Synthetic bone substitutes (alloplasts) are biocompatible, osteoconductive, with various porosities, densities, geometries and resorption rates. There are calcium phosphate based grafting materials (tricalcium phosphate, biphasic calcium phosphate), calcium sulfate, biocompatible composite polymers and other ceramics (microporous hydroxylapatite) [37, 40]. They are able to form

strong interface with surrounding bone and have different mechanical properties restricting wider range of use [41]. There are composed bioactive hybrids (bioactive glasses) having bioactivity of ceramics with flexibility of the polymers [39]. These ceramics can be characterized having osteoconductive properties with long degradation period. For the 4 to 12 months augmentation period when patients wish to postpone the implantation of later.

- *Fillings for long-term augmentation* with low resorption in the body are kept to be non-resorbable (e.g. particulate, dense hydroxylapatite). Alveoli augmented with these materials are not intended for implantation.

There is one more group of materials called osteoactive agents. An osteoactive agent is any material which has the ability to stimulate the deposition of bone [42]. They can be classified in several groups: osteoinducers, osteopromotors (e.g. transforming growth factor β (TGF- β)) and bioactive peptides. The first two compounds are growth factors. They are responsible for normal physiological processes and biological activities (e.g. DNA synthesis, cell proliferation). The third compound are morphogens (e.g. bone morphogenetic protein (BMP)). They are diffusible substances in embryonic tissues that influence the evolution and development of form, shape or growth [39]. Bioactive polypeptides (e.g. P-15, OSA-117MV) can act as osteoinducers or osteoenhancers. These materials and their effects are under investigation with possible wide use in bone regeneration.

Platelets contain a big amount of various growth factors (TGF- β , PDGF, IGF, FGF) [43]. These factors are realised into the tissues after injury and act as differential factors on regeneration of periodontal tissues. PDGF-IGF can increase bone healing in defects associated with dental implants and teeth [44]. Platelet rich plasma (PRP) is one source of high concentrated platelets that could be used in conjunction with autogenous bone grafts, biomaterials in bone regeneration [45, 46].

Stem cells have high importance in oral rehabilitation while contemporary biomaterials have clear disadvantages. There is a need for development of new grafting materials and methods. Human mesenchymal stem cells (MSCs) are capable to differentiate into various mesenchymal tissues (for oral rehabilitation it is very important to develop MSCs differentiation into osteoblasts) [47]. They can form hybrid grafts with biomaterials [29].

A recent study in dogs was done to assess the level of resorption of alveolar walls when surrounding tooth tissue is damaged using soft and

bone transplants after a tooth extraction [15]. The obtained data confirmed that the injurious procedure – mucoperiosteal flap elevation increased resorption of extraction socket walls whereas the usage of bone graft substitute and gingival transplants reduced, in comparison with conventional extraction of the tooth. However, buccal mucoperiosteal flap reflection reduced success of augmentation in case of intraalveolar augmentation. Additional extraalveolar augmentation increased by about 22 per cent of horizontal width of socket [13].

The main local contraindication for bone augmentation during the removal of teeth is an inflammatory process.

General contraindications [13]:

- Unsatisfactory overall body condition or the existence of serious related diseases (especially diabetes, tumors).

- Used medications (e.g. bisphosphonates, immunosuppressants).

The negative influence of smoking is identified separately [13].

Genetically determined healing changes may be inferred (when different osteoclast activity is known).

Indications – favourable maintenance of alveolar bone ridge volume after tooth extraction:

- high aesthetic requirements;
- narrow alveolus crest;
- thin buccal and lingual alveolar walls (thinner than 2 mm) and a thin gingival biotype;
- alveolar ridge fenestrations;
- immediate implantation;
- temporarily unavailable implantation (implant can be placed in at least 4 to 6 months, the patient's bones are still growing (children) and so on.)

INTRAALVEOLAR AUGMENTATION PRINCIPLES AND POSSIBLE MODIFICATIONS

There is a variety of techniques of preservation of bone volume material usage [2, 11, 15, 17, 25, 30, 33, 34, 36, 37, 40, 48, 49]. Bone volume preservation is very important to obtain good aesthetic results [2]. After tooth removal buccal plate integrity can be assessed. Often defects for the alongside progressive pathological processes or anatomical features are monitored. It was found that if buccal defect is up to one-third of the total width of socket between adjacent teeth in mediobuccal direction and do not reach adjacent teeth surrounding bone in labio-palatal direction then good augmentation results can be expected even mentioned buccal defects are

observed [13]. Augmentation procedures principles often recommended in literature are presented [13, 25]:

- The tooth extraction and alveolar bone ridge preparation (Fig. 4, 5).
- Socket grafting with bone substitute (Fig. 6).
- Bone substitute protection with collagen and stabilization with suture, covering with liquid impermeable coating material (Fig. 7, 8).
- Dental arch defect filling with a provisional restoration.

After atraumatic tooth extraction alveolus is irrigated with 0.12 per cent chlorhexidine solution (antiseptic preparation), and later a thorough overhaul of bone is performed: all granulation tissues are removed from the socket. Profusely irrigated with saline. It is important to assess the buccal alveolar contours possible damages, fenestrations. If alveolar bone ridge intact augmentation procedure becomes more simple. Socket is packed with particulated bone graft (for example, xenogenic bone substitute) to the alveolar pit limit (to the gums) and condensed easily by hand instrument (to avoid high condensation). Collagen membranes or collagen plugs are usually recommended to protect the material (depending on methodology). When alveolar bone walls intact and mucoperiosteal flap is not elevated, it is convenient to use resorbable collagen which is applied in a few layers or plug (subject to the manufacturer of a product) over the graft. Some authors use only collagen for preservation of alveoli, without bone substitutes while others recommend to cover intact alveoli only with resorbable or non-resorbable (titanic, PTFE) membranes which are partially or fully closed with mobilized mucoperiosteal flap and sutured). Collagen is usually stabilized more coronal through the soft tissues by using surgical horizontal mattress sutures. The use of collagen has evidence of better soft tissue healing process [50]. Collagen surface is lubricated by isobutyl cyanoacrylate to be protected from oral liquids (not all authors recommend it). The temporary restoration is attached to in a way that it submerged into soft tissues of socket no more than 2 mm and could have a broad base, and could maintain gingival contours and papilla.

In the case of buccal (labial) alveolar bone defects prior to augmentation, it is appropriate to use collagen membranes for complete protection of bone graft from the soft tissues of buccal site. Buccal mucoperiosteal flap of pouch shape is elevated (about 2 mm to the sides of the defect), so as to cover buccal bone defect by membrane. The membrane must cover the entire defect and overlap

of about 2 mm in intact bone, in order to avoid soft tissue ingrowth. Subsequently, alveolar socket is condensed with particulated graft (for larger defects it is recommended to use a higher autogenous or allogeneic bone ratio with materials recommended for the average augmentation by mixing or applying stratification (coronary part is filled with autogenous or allogeneic bone)), remaining collagen membrane is adapted over it, a collagen plug is placed in, etc. Further postoperative care of the surgical site is usual (some authors recommend antibioticoprophylaxis (ABP) [37, 51]). Sutures are removed after 7-14 days. After the healing period it needs to be evaluated clinically, radiological observation of augmented area and further surgery are carried out.

After the removal of the tooth for soft tissue thickening, quality improvement, and further surgery (e.g. bone block) to increase success, rotated soft tissue flaps can be used to improve aesthetics, which may be with the epithelium or without from palatal (lingual) or labial (buccal) side. It will also be used for connective tissue graft (free or pedicled) [52]. Keratinized gingival or combined epithelized-subepithelial connective tissue autogenous transplants may be used for covering bone graft in socket [34, 51]. Palatal mucosa of 2-3 mm thickness graft corresponding to the gingival defect volume after tooth extraction can be used. It is adapted over bone substitute in socket carefully and anchoring with the surgical suture to de-epithelised gingival margins.

Immediate implantation for alveolar ridge preservation during atraumatic tooth extraction has still controversial hypotheses. Some studies give positive results with bone preservation after implant placement in the fresh alveolus [53], while others do not [54, 55].

Advantages of alveolar augmentation

- Optimal implant position selection option.
- Optimal long-term aesthetic and functional outcome reached after prosthodontic treatment.
 - Need of less complex additional bone and/or soft tissue augmentation procedures or reduction of the volume during later dental implant placement procedure [25].
 - Orthodontic treatment with optimal results (after tooth removal interdental spaces are closed with braces systems) [11].

Disadvantages of bone preserving procedures

- Dental implantation is possible only around 4-6 months.
 - Tooth extraction and additional augmentation procedures are longer, more complex.

- A need for additional measures (instruments, materials).
- Procedures are more technically sensitive.
- It may not be enough of saved bone during implantation – may be a need for additional augmentation.
- Further risk of failure of the augmentation procedures remains (inflammatory processes, membrane exposure, graft necrosis)
- During the procedures there is the lack of rigid (keratinized) gums.
- In acute inflammatory processes augmentation is impossible.
- Significantly increased the cost of the procedures.

Implant placement in post-extractional sites without socket grafting

Contemporary treatment options are extensive. However, you can choose other types of treatment methods to ensure a good long-term morphological, aesthetic and functional result after implantation in post-extraction sites. The literature contains much evidence that the guided bone regeneration - GBR with implantation after tooth removal in a healing bone, when buccal bone defect do not reach the

adjacent teeth bone and the implant may be placed in an appropriate spatial position to be successful [13]. Found larger bone defects are reconstructed with complex surgical operations (the bone block, vertical alveolar ridge osteotomy, Le Fort I osteotomy, etc.).

RESULTS AND CONCLUSIONS

Atraumatic tooth extraction is very important requirement for soft and hard post-extraction site tissues preservation. Augmentation of tooth alveoli after tooth removal is more often applied in recent practice and is effective when applying to limited post-extraction osseous and soft tissue defects. More and more surgical procedures are presented, they are evolving. There are not enough studies to determine the best method, or the most appropriate materials, and yet there are no special techniques of long-term results and assessment of the outcome of dental implantation after such augmentations. No clarification to the impact to augmentation effectiveness has former pathology of augmented area, because of which tooth had been removed. There are no standardized guidelines for appropriateness of antibiotic use.

REFERENCES

1. Vanchit J, De Poi R, Blanchard S. Socket preservation as a precursor of future implant placement : review of the literature and case reports. *Compend Contin Educ Dent* 2007;28:646-54.
2. Gonshor A. Extraction site and ridge preservation, a peer-review publication. Available from: URL: <http://www.ineedce.com/courses/1440/PDF/ExtractionSiteandRidge.pdf>. Accessed January 26, 2012.
3. Irinakis T. Future implant placement. *J Can Dent Assoc* 2006;72:917-22.
4. Bartee BK. Extraction site reconstruction for alveolar ridge preservation. Part 1: Rationale and materials selection. *J Oral Implantol* 2001;27:187-93.
5. Schropp L, Wenzel A, Kostopoulos L, Karring T. Bone healing and soft tissue contour changes following single-tooth extraction: a clinical and radiographic 12-month prospective study. *Int J Periodontics Restorative Dent* 2003;23:313-23.
6. Meccall RA, Rosenfeld AL. Influence of residual ridge resorption patterns on implant fixture placement and tooth position. 1. *J Periodontics Restorative Dent* 1991;11:8-23.
7. Atwood DA. Some clinical factors related to the rate of resorption of residual ridges. *J Prosthet Dent* 1962;12:441-50.
8. Atwood DA. Postextraction changes in the adult mandible as illustrated by microradiographs of midsagittal section and serial cephalometric roentgenograms. *J Prosthet Dent* 1963;13:810-16.
9. Pietrokovski J, Massler M. Alveolar ridge resorption following tooth extraction. *J Prosthet Dent* 1967;17:21-7.
10. Amler MH. The time sequence of tissue regeneration in human extraction wounds. *Oral Surg Oral Med Oral Pathol* 1969;27:309-18.
11. Schropp L. Radiographic and clinical procedures in single-tooth implant treatment. Available from: URL: <http://www.odont.au.dk/rad/LS-Thesis.pdf>. Accessed March 2008.
12. Lindhe J, Lang NP, Karring T. Clinical periodontology and implant dentistry 4th ed. Copenhagen: Blackwell Publ Co; 2003. p. 865-77.
13. Chen S, Buser D. ITI Treatment Guide. Volume 3: Implant placement in post-extraction sites. treatment options. Berlin: Quintessence Publ Co; 2008. p.11-5, 19, 30-1, 143-52.
14. Araujo MG, Lindhe J. Dimensional ridge alterations following tooth extraction. An experimental study in the dog. *J Clin Periodontol* 2005; 32:212-18.
15. Fickl S, Zuhr O, Wachtel H, Bolz W, Huerzeler M. Tissue alterations after tooth extraction with and without surgical trauma: a volumetric study in the beagle dog. *J Clin Periodontol* 2008;35:356-63.
16. Knezovic-Zlataric D, Celebic A. Resorptive changes of maxillary and mandibular bone structures in removable denture wearers. *Acta Stomatol Croat* 2002;36:261-5.
17. Bartee BK. Extraction site reconstruction for alveolar ridge preservation. Part 2: Membrane-assisted surgical technique. *J Oral Implantol* 2001;27:194-97.
18. Lekovic V, Camargo PM, Klokkevold PR, Weinlaender M, Kenney EB, Dimitrijevic B, et al. Preservation of alveolar bone in extraction sockets using bioabsorbable membranes. *J Periodontol* 1998;69:1044-49.
19. Batal HS, Jacob G. Surgical extractions. In: Koerner KR, editor. *Manual of minor oral surgery for the general dentist USA* (Iowa): Blackwell Munksgaard; 2006. p.19-48.
20. Peterson LJ, Ellis E, Hupp JR, Tucker MR. Contemporary oral and maxillofacial surgery. 4th ed. St. Louis: Mosby; 2003. p. 76-246.
21. Adeyemo WL, Ladeinde AL, Ogunlewe MO. Influence of trans-operative complications on socket healing following dental extractions. *J Contemp Dent Pract* 2007;8: 52-9.
22. Lieven V. Post-extraction molariform tooth drift and alveolar grafting in horses. Available from: URL: http://lib.ugent.be/fulltxt/RUG01/001/221/881/RUG01-001221881_2010_0001_AC.pdf. Accessed January 26, 2012.
23. Serino G, Rao W, Iezzi G, Piattelli A. Polylactide and

- polyglycolide sponge used in human extraction sockets: bone formation following 3 months after its application. *Clin Oral Implants Res* 2007;19:26-31.
24. Bach N, Baylard JF, Voyer R. Orthodontic extrusion: periodontal considerations and applications. *J Can Dent Assoc* 2004;70:775-80.
 25. Sclar AG. Strategies for management of single-tooth extraction sites in aesthetic implant therapy. *J Oral Maxillofac Surg* 2004;62(9 Suppl 2):90-105.
 26. Tischler M, Misch CE. Extraction site bone grafting in general dentistry: review of applications and principles. *Dent Today* 2004;23:108-13.
 27. Clokie CM, Yau DM, Chano L. Autogenous tooth transplantation: an alternative to dental implant placement. *J Can Dent Assoc* 2001;67:92-6.
 28. Ostler M, Kokich V. Alveolar ridge changes in patients congenitally missing mandibular second premolars. *J Prosth Dent* 1994;71:144-9.
 29. Sándor GKB, Lindholm TC, Clokie CML. Bone regeneration of the crano-maxillofacial and dento-alveolar skeletons in the framework of tissue engineering. In : *Ashmmakhi N, Ferretti P, editors. Topics in Tissue Engineering*. 2003. p. 5-6, 24-5. Available from: URL: http://www.oulu.fi/spareparts/ebook_topics_in_t_e/abstracts/sandor_01.pdf. Oulu, Finland. Accessed January 26, 2012.
 30. John V, De Poi R, Blanchard S. Socket preservation as a precursor of future implant placement: review of the literature and case reports. *Compend Contin Educ Dent* 2007;28:646-53, 654, 671.
 31. Spray JR, Black CG, Morris HF, Ochi S. The influence of bone thickness on facial marginal bone response: stage 1 placement through stage 2 uncovering. *Ann Periodontol* 2000;5:119-28.
 32. Lekovic V, Kenney EB, Weinlaender M, Han T, Klokkevoeld P, Nedic M, et al. A bone regenerative approach to alveolar ridge maintenance following tooth extraction. Report of 10 cases. *J Periodontol* 1997;68:563-70.
 33. Oghli AA, Steveling H. Ridge preservation following tooth extraction: a comparison between atraumatic extraction and socket seal surgery. *Quintessence Int* 2010;41:605-9.
 34. Lindhe J, Lang NP, Karring T. Clinical periodontology and implant dentistry. 5th ed. Vol 1. Copenhagen: Blackwell Munksgaard; 2008.
 35. Novaes AB Jr, de Barros RR. Acellular dermal matrix allograft. The results of controlled randomized clinical studies. *J Int Acad Periodontol* 2008;10:123-9.
 36. Beck TM, Mealey BL. Histologic analysis of healing after tooth extraction with ridge preservation using mineralized human bone allograft. *J Periodontol* 2010;81:1765-72.
 37. Sisti A, Canullo L, Mottola MP, Covani U, Barone A, Botticelli D. Clinical evaluation of a ridge augmentation procedure for the severely resorbed alveolar socket: multicenter randomized controlled trial, preliminary results. *Clin Oral Implants Res* 2011;23:526-35.
 38. Araujo MG, Lindhe J. Socket grafting with the use of autologous bone: an experimental study in the dog. *Clin Oral Implants Res* 2011;22:9-13.
 39. Allegrini SJr, Koenig BJr, Allegrini MR, Yoshimoto M, Gedrange T, Fanghaenel J, et al. Alveolar ridge sockets preservation with bone grafting-review. *Ann Acad Med Stetin* 2008;54:70-81.
 40. Lee DW, Pi SH, Lee SK, Kim EC. Comparative histomorphometric analysis of extraction sockets healing implanted with bovine xenografts, irradiated cancellous allografts, and solvent-dehydrated allografts in humans. *Int J Oral Maxillofac Implants* 2009;24:609-15.
 41. LeGeros R. Properties of osteoconductive biomaterials: calcium phosphates. *Clin Orthop Relat Res* 2002;395:81-98.
 42. Clokie CML, Sándor GKB. Bone : present and future. In: *Babush C, editor. Dental implants: The art and science*. Philadelphia: W.B. Saunders Company; 2001. p. 59-84.
 43. Tözüm TF, Demiralp B. Platelet-rich plasma : a promising innovation in dentistry. *J Can Dent Assoc* 2003;69:664.
 44. Khoury F, Antoun H, Missika P. Bone augmentation. In: *Oral Implantology*. Berlin: Quintessence Publishing Co; 2007. p.77, 204, 207-8.
 45. Landesberg R, Moses M, Karpatkin M. Risks of using platelet rich plasma gel. *J Oral Maxillofac Surg* 1998;56:1116-7.
 46. Shi B, Zhou Y, Wang YN, Cheng XR. Alveolar ridge preservation prior to implant placement with surgical-grade calcium sulfate and platelet-rich plasma: a pilot study in a canine model. *Int J Oral Maxillofac Implants* 2007;22:656-65.
 47. Livingston SP, Gordon S, Archambault M, Kadiyala S, McIntosh K, Smith A, et al. Mesenchymal stem cells combined with biphasic calcium phosphate ceramics promote bone regeneration. *J Mater Sci Mater Med* 2003;14:211-8.
 48. Jung RE, Siegenthaler DW, Hämmerle CH. Postextraction tissue management: a soft tissue punch technique. *Int J Periodontics Restorative Dent* 2004;24:545-53.
 49. Saad A, Al-Harbi, Wendell AE. Preservation of soft tissue contours with immediate screw-retained provisional implant crown. *J Prosthet Dent* 2007;98:329-32.
 50. Jeschke M.G, Sandmann G, Schubert T, Klein D. Effect of oxidized regenerated cellulose/collagen matrix on dermal and epidermal healing and growth factors in an acute wound. *Wound Rep Reg* 2005;13:324-31.
 51. Stimmelmayer M, Allen EP, Reichert TE, Iglhaut G. Use of a combination epithelialized-subepithelial connective tissue graft for closure and soft tissue augmentation of an extraction site following ridge preservation or implant placement: description of a technique. *Int J Periodontics Restorative Dent* 2010;30:375-81.
 52. Stefani CM, Machado MA, Sallum EA, Sallum AW, Toledo S, Nociti FH Jr. Platelet-derived growth factor/insulin-like growth factor-1 combination and bone regeneration around implants placed into extraction sockets: a histometric study in dogs. *Implant Dent* 2009;9:126-31.
 53. Paolantonio M, Dolci M, Scarano A, d'Archivio D, di Placido G, Tumini V, et al. Immediate implantation in fresh extraction sockets. A controlled clinical and histological study in man. *J Periodontol* 2001;72:1560-71.
 54. Botticelli D, Berglundh T, Lindhe J. Hard-tissue alterations following immediate implant placement in extraction sites. *J Clin Periodontol* 2004;31:820-8.
 55. Sanz M, Cecchinato D, Ferrus J, Pjetursson EB, Lang NP, Lindhe J. A prospective, randomized-controlled clinical trial to evaluate bone preservation using implants with different geometry placed into extraction sockets in the maxilla. *Clin Oral Implants Res* 2010;21:13-21.

Received: 11 05 2011

Accepted for publishing: 18 03 2012