

# A five years clinical evaluation of sealed occlusal surfaces of molars

*Ruta Bendinskaite, Vytaute Peciuliene, Vilma Brukiene*

## SUMMARY

**Background.** Air-abrasion can be used for enamel preparation before fissure sealing as well as acid etching which is the evidence-based method for enamel preparation before sealing.

**Aim.** The aim of this study is to evaluate the status of sealed occlusal surfaces of the first permanent molars after one, two, and five years and to compare consequence of using the two different methods for enamel preparation before sealing.

**Materials and methods.** At the baseline of the study 88 children of the age from 6 to 9 with caries-free permanent molars randomly received 185 sealants after using the air-abrasion system KCP 2000 PLUS (ADT Inc.) and 121 sealants using the acid etching method with Vocodid (VoCo). Fissurit F (VoCo) was used for sealing. The status of occlusal surfaces of molars was scored as caries-free or decayed/restored by visual clinical assessment evaluation after one, two, and five years.

**Results.** The sealants retention rate was 97.2%, 91.9%, 61.2% in the air-abrasion group and 96.3%, 92.6%, 62.4% in the acid etching group after one, two, and five years, respectively. The results showed 98.2%, 98.0%, 89.8% caries free occlusal surfaces of molars prepared with air-abrasion method and 100%, 100%, 94.6% caries free occlusal surfaces of molars prepared with acid etching method after one, two, and five years respectively.

**Conclusion.** The differences between the two methods: air-abrasion and acid etching in terms of sealant retention rate and caries development appeared to be statistically insignificant ( $p > 0.05$ ).

**Key words:** pits and fissures, caries, sealants, air-abrasion, acid etching.

## INTRODUCTION

Dental sealants act as coatings preventing growth of bacteria that promote decay in pits and fissures of molar teeth and are applied on occlusal surfaces of the teeth at risk. Children who have their molar teeth covered by sealants in general are less exposed to dental decay in pits and fissures. Non-sealed teeth required to be restored approximately 50% more frequently compared to their sealed counterparts, when fissure sealant treatment was used routinely without caries risk evaluation as in real life, not University, conditions [1].

Acid etching is the evidence-based method for enamel preparation before fissure sealing [2]

while the air-abrasion system has been introduced for preparing pits and fissures before sealant placement and uses a stream of aluminium oxide particles delivered by compressed air to the surface of tooth for the purpose of abrading tooth structure [3]. The air-abrasion system, besides roughening of enamel mechanically, opens questionable fissures [4, 5] and removes caries before the fissures are sealed similar as it could be done with bur [6]. Such opening of pits and fissures facilitates diagnose of caries and improves retention of sealants [7-9]. It could be hypothesised that sealants after air-abrasion of pits and fissures will show better retention rate and because of that less caries lesions.

Effectiveness of fissure sealants has been proved in spite of the fact that it depends on retention of sealants [10]. Reported decrease of sealants retention rate is up to 60% and less after several years [1-13]. Despite all the efforts to seal the pits and fissures properly, measurable failure rate of sealants (5-10% per year) could be observed [14]. Acid

*\*Institute of Odontology Faculty of Medicine Vilnius University, Lithuania*

*Ruta Bendinskaite\* – D.D.S, PhD, lecturer*

*Vytaute Peciuliene\* – D.D.S, PhD, prof.*

*Vilma Brukiene\* – D.D.S., PhD, assoc. prof.*

*Address correspondence to Dr. Ruta Bendinskaite, Zalgirio 115, Vilnius, Lithuania.*

*E-mail address: rutabend@gmail.com*

etched pits and fissures after loss of sealants tend to decay because of retention of microbial plaque in closed pits and fissures [15].

Several studies have reported conflicting results when air-abrasion treatment was used before fissure sealing. Most of them were carried out in vitro [16-24]. Unfortunately, we could not find any data in the scientific literature enabling us to compare air-abrasion and acid-etching methods as methods for enamel preparation for fissure sealing in terms of possible carries subsequent development in relation to caries.

The aim of this study is to evaluate the status of sealed occlusal surfaces prepared using two different methods (air-abrasion and acid etching) in terms of presence or loss of sealants and presence of caries after one, two, and five years.

## MATERIALS AND METHODS

A resin-based sealant material containing fluoride was applied to first permanent molars of children using two methods in the parallel-group study design. The Ethics Committee of the Clinic of Odontology of Faculty of Medicine of the Vilnius University has approved the study. All the children participated in the study and their parents were informed before the examination and sealing and gave their consent to treatment.

Of total, 88 children at the age of 6 to 9 years routinely attending Zalgiris Clinic of Vilnius University Hospital participated in the study and their 306 teeth were covered with sealants). A sample size was estimated assuming the value of standardized difference of 0.44 calculated using 60% of established sealants retention rate after acid etching, and 80% of expected sealants retention rate in the air-abrasion group after 5 years after sealing, and 90% power with using a cutoff for statistical significance of 0.05 using the nomogram [25].

At the baseline status of occlusal surfaces was evaluated before sealing under standardized conditions by a trained examiner using the clinical visual assessment by WHO criteria at the level of dentine caries [26]. Before the examination teeth were cleaned with paste (Klint, Voco) and brush in slow speed handpiece, rinsed and dried. A flat mirror and blunt exploration probe were used. The first molars that did not erupt or were still erupting at the baseline were evaluated after every 6 months and included in the study after complete eruption in cases when the teeth were found to be without caries. Previously sealed first permanent molars or the ones with detectable dentine caries or fillings initially were excluded from the study. No other

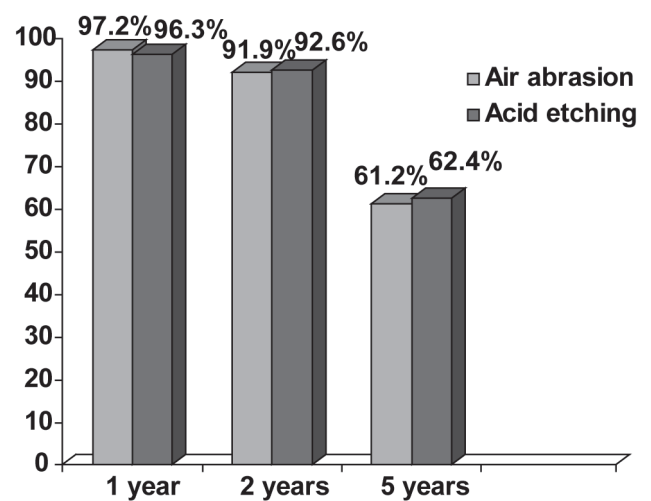


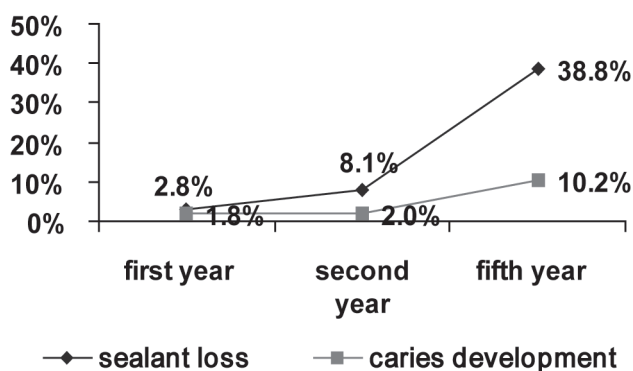
Fig. 1. Retention rate of sealants in air-abrasion and acid etching groups after one, two, and five years

exclusion criterion was applied.

The participants were randomly allocated into two treatment groups. A parallel-group randomization was applied as follows: every third child has been assigned to the acid etching group, while the other two – to the air-abrasion group.

306 molars in total were sealed with light-polymerized resin-based sealant material with fluoride Fissurit F (VoCo): 185 using the air-abrasion system KCP 2000 PLUS (ADT Inc.) and 121 using the acid etching method with Vococid (VoCo). The sealants were applied by an operator working together with a chair-side assistant. The pits and fissures preparation method differed by the group. For the air-abrasion group the operator used 50  $\mu$  alumina oxide particles and air-abraded pits and fissures for 3 seconds at 120 psi (pounds per square inch) (0,8 MPa) pressure. The nozzle tip was held perpendicular to the surface at the distance of 1 to 2 millimeters. After the air-abrasion the operator rinsed the tooth with water for 30 seconds and thoroughly dried it. For the acid etching group, the operator etched pits and fissures with a 35 percent phosphoric acid gel for 30 seconds using disposable tips, also rinsed the tooth with water for 30 seconds and thoroughly dried it. The material was applied to the prepared surfaces according to the manufacturers' instructions using disposable syringe tips and blunt exploration probe for the purpose of excluding air bubbles and it was polymerized by curing light for 40 seconds with power output of 600 milliwatts per square centimeter. At the end the operator checked the occlusion, adjusted the sealants with finishing bur and applied fluoride varnish.

The sealed teeth were observed for a 5-years period. The examination of teeth took place at the baseline, after one, two, and five years after



**Fig. 2.** Caries development and sealants retention in the air-abrasion group

the application of the sealants. The subjects were examined under standardized conditions using flat mirror and blunt exploration probe by the same trained examiner. During recall visits the examiner did not know the method used for enamel preparation, therefore the examination is of single-blind type. The condition of occlusal surfaces of molars was evaluated using clinical visual assessment by the WHO criteria [26]. Evaluation has been carried out as follows. A tooth has been registered as sound in such cases when no dentine caries was detected or carious whenever dentine caries including non-cavitated and/or restoration were detected. Sealants were classified as present (totally or partially) or lost.

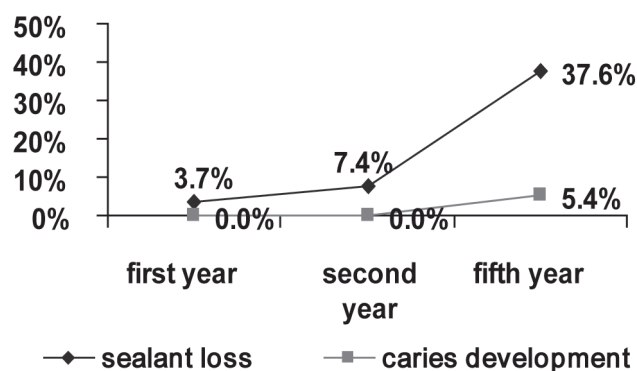
Statistical analysis of sealants retention and caries development using the two methods of teeth sealing was carried out with the Chi-square test. Effects with  $p < 0.05$  were considered to be significant.

## RESULTS

After one, two, and five years after what sealing it was possible for us to evaluate 168, 153 and 98 sealants respectively in the air-abrasion group and 109, 109 and 93 sealants respectively in the acid etching group. The dropout rate in this study was 37% at the end of the 5-year period.

Caries lesions in the pits and fissures of the sealed teeth in both groups during the 5-year follow-up were few. Dental decay was detected in the teeth where sealants were found to be defective or lost. Sealants retention rates after one, two, and five years were similar in both tooth preparation groups and declined during the time-period (Fig. 1).

After 5 years in 176 molars in total from both groups no caries was observed, which makes up 92.15% rate. In the air-abrasion group in one year period and in two year period after sealing only 3 caries lesions/ fillings were found, while in five years, 10 such cases were observed. No caries was



**Fig. 3.** Caries development and sealants retention in the acid etching group

detected in one and two years, while 5 caries lesions after five years in the acid etching group were observed (Fig. 2, 3). However, the difference in the caries rate was not statistically significant ( $p > 0.05$ ).

## DISCUSSION

In the present study we investigated the status of prepared and sealed occlusal surfaces using two different methods over five years. Air-abraded and sealed or acid etched and sealed fissures showed high sealant retention rate, however, some caries lesions were found in cases of loss of sealants after few years. The present study findings confirmed the results of other studies in terms of retention of sealants.

The effectiveness of dental sealants is well established in numerous studies [12, 13]. It is obvious for high caries-risk individuals [1], for the individuals with low or moderate caries activity [27] and for the individuals with teeth with incipient lesions [28]. Nevertheless, literature review shows that effectiveness of dental sealants depends on retention of the sealant [10, 29].

There are many studies on retention of sealants with diverse results. The results of the present study show that 38.8% of sealants after air-abrasion and 37.6% of sealants after acid etching were lost completely after five years. It well agrees with most of the studies. For example, Horowitz and Poulsen reported 44% sealant loss rate after 5 years [30], Francis et al. reported 34.3% rate of complete loss of sealants after five years after sealing [31]. The review of the scientific literature showed the tendency of decline of the retention rate of an autopolymerized or visible-light-cured sealant from 83% in one year to 55% in seven years. Similarly, the mean of complete retention of sealants rate declines from 92% after one year to 66% after seven years [32]. Still the extremely low retention rate of sealants in the five-year period could be observed for composite

resin 86%, and for glass ionomer 88% [33].

The aim of the present study is to reveal the presence of caries lesions on the occlusal surfaces of the sealed molars in mentioned time periods of one, two, and five years. As it was mentioned earlier, we could not find any data in the scientific literature comparing air-abrasion and acid etching methods for enamel preparation for consequent fissure sealing, in terms of caries revealing after sealant loss. There could be found various studies on acid etching technique in literature. The results found in these studies could, nevertheless, be compared with the results of the present study as we did not find statistically significant differences between two methods regarding sealants retention and occlusal caries development.

According to literature, there was a low prevalence of dentine caries associated with the sealed teeth (2.8%) [34]. Even more, sealing non-cavitated caries in permanent teeth appears to be effective in reducing caries progression: the median annual percentage of non-cavitated lesions progressing was 2.6% for sealed and 12.6% for unsealed carious teeth [35]. The other study confirms these results: for initially incipient surfaces the five-year decay rate was 10.8% for sealed surfaces and 51.8% for non sealed surfaces and initially sound surfaces had a decay rate of 8.1% for sealed surfaces and 12.5% for non sealed surfaces [28].

As mentioned earlier, the present study did not show statistically significant differences between acid etching and air-abrasion methods regarding sealants retention and occlusal caries development. Whereas effectiveness of dental sealants placed using acid etching is well established already in numerous studies [12, 13], it could be presumed that air-abrasion as well as acid etching perform effectively in fissure sealing according the results of present study. However, the hypothesis that sealants retention rate will be higher consequently pits and fissures tend to decay less after air-abrasion of pits and fissures before sealing should be rejected.

The present study revealed the result of 92.15% of the teeth without caries after five years after sealing. These results are similar [36] or even slightly better comparing with data available in the scientific literature: 18% carious or filled surfaces in 3 years [4] and 12.2% of tooth surfaces carious after five years after sealing [31]. During longer follow up periods (7-10+ years) it was found that 30-40% of sealed molars and 60-80% of non-sealed molars were restored [37] and the median percentage of sealed first molars becoming carious and/or restored increases from 4% after one year to 31% after seven years [32]. The tendency of the higher decay rates

can be observed in the studies where sealants are applied by general practitioners in a routine clinical practice [3]. As present clinical trial was carried out at the University clinic under controlled conditions, the higher effectiveness of pits and fissure sealants was achieved.

Besides retention of sealants and caries development, two other aspects of the methodology of the study, caries diagnosis and opening of fissures, deserve a comment.

Visual clinical examination has been the major method in the routine clinical practice [38], and therefore it became the method of our choice in this study to get closest to real life, every day routine practice, conditions. Radiographic examination is not imposed by Lithuanian dental health regulatory authorities to be performed before sealant placement yet and thus was not exercised during the present study. However, accurate diagnosis of occlusal dental caries is challenging and the use of visual clinical examination alone could result in omitting caries in closed fissures unless cavitation or radiographic evidence is present [38-41]. Open fissures facilitate diagnose of occlusal caries compared with closed ones [42]. This could partially explain the fact that more caries lesions were found in the air-abrasion group in the teeth with opened pits and fissures.

Enamel preparation before occlusal surface sealing can be done using different methods [6, 20, 21]. During enamel preparation process, which takes place before sealing, pit and fissures could be opened (air-abrasion, bur) or left closed (acid etching). The present study compares the status of occlusal surface after applying two different methods of enamel preparation: acid etching and air-abrasion over the five year period. The results of the present study reveal equal performance results of applying air-abrasion and acid etching methods for enamel preparation before fissure sealing in respect of retention of sealants. However, these methods treat fissures differently. Acid etching of enamel roughens the surface without destroying anatomy of the pits and fissures [43] and after loss of sealant pits and fissures remain closed. Sandblasting with alumina particles brings the possibility to roughen and remove enamel. Therefore, after opening of pits and fissures it is easier as mentioned earlier to diagnose fissure caries [5, 42] and achieve better retention of the sealant because of increased surface for adhesion [4]. On the other hand, in case of lost sealants pits and fissures are left open.

According to the studies mentioned in the scientific literature, there was no significant difference in enamel loss between sandblasting at the low pressure of 0.1 MPa in combination with the short exposure

time of 1 second and acid etching with 37% phosphoric acid for 30 seconds. However, sandblasting with a longer exposure time (5 s) or higher pressures (0.2-0.3 MPa) resulted in a significantly higher amount of enamel loss [4]. According to the KCP 2000 PLUS air-abrasion unit manufacturer's (ADT Inc.) instruction 120 psi pressure should be used for enamel preparation before fissure sealing. In the present study the pressure of 120 psi (0,8 MPa) and the exposure time of 3 seconds were used, therefore, some amount of enamel was lost.

The present study results showed more caries lesion in opened fissures left after loss of sealants in the air-abrasion group. Beside easier caries diagnostic in opened pits and fissures, it could be explained by accumulation of plaque, resulting in caries lesion after sealant loss in opened pits and

fissures as well as in the closed ones [15]. However, statistically significant difference between caries in the air-abraded and acid etched pits and fissures after one, two, and five years period has not been found.

## CONCLUSIONS

This investigation brings out the following conclusions:

1. Retention rate of sealants on the first permanent molars appears to be high within the five-year period, whatever method is used: the enamel air-abrasion and acid etching.
2. The differences between results after applying the two methods regarding the sealants retention and caries development were not statistically significant after five years ( $p > 0.05$ ).

## REFERENCES

1. Ahovuo-Saloranta A, Hiiri A, Nordblad A, Mäkelä M, Worthington HV. Pit and fissure sealants for preventing dental decay in the permanent teeth of children and adolescents. *Cochrane Database of Systematic Reviews* 2008;4: Art. No.: CD001830. DOI: 10.1002/14651858.CD001830.pub3.
2. Beauchamp J, Caufield PW, Crall JJ, Donly K, Feigal R, Gooch B, et al. Evidence-based clinical recommendations for the use of pit-and-fissure sealants. A report of the American Dental Association Council on Scientific Affairs. *JADA* 2008;139:257-68.
3. Goldstein RE, Parkins FM. Air-abrasive technology: its new role in restorative dentistry. *JADA* 1994;125:551-7.
4. Heyduck C, Meller C, Schwahn C, Splieth CH. Effectiveness of sealants in adolescents with high and low caries experience. *Caries Res* 2006;40:375-81.
5. Heller KE, Reed SG, Bruner FW, Eklund SA, Burt BA. Longitudinal evaluation of sealing molars with and without incipient dental caries in a public health program. *J Public Health Dent* 1995;55:148-53.
6. Khanna R, Pandey RK, Singh N, Agarwal A. A comparison of enameloplasty sealant technique with conventional sealant technique: A scanning electron microscope study. *J Indian Soc Pedod Prev Dent* [serial online] 2009;27:158-63. Available from: <<http://www.jisppd.com/text.asp?2009/27/3/158/57096>>.
7. do Rego MC, de Araujo C. A 2-year clinical evaluation of fluoride containing pit and fissure sealants placed with an invasive technique. *Quintessence Int* 1996;27:99-103.
8. Garcia-Godoy F, de Araujo FB. Enhancement of fissure sealant penetration and adaptation: The enameloplasty technique. *J Clin Pediatr Dent* 1994;9:13-8.
9. Xalabarde A, Garcia-Godoy F, Boj JR, Canaida C. Fissure micromorphology and sealant adaptation after occlusal enameloplasty. *J Clin Pediatr Dent* 1996;20:299-304.
10. Mejäre I, Lingström P, Petersson LG, Holm AK, Twetman S, Källestål C, et al. Caries-preventive effect of fissure sealants: a systematic review. *Acta Odontol* 2003;61:321-30.
11. Ripa W. Sealants revisited: An update of the effectiveness of pit and fissure sealants. *Caries Res* 1993;27:77-82.
12. Deery C, Fyffe HE, Nugent Z, Nuttall NM, Pitts NB. Integrity, maintenance and caries susceptibility of sealed surfaces in adolescents receiving regular care from general dental practitioners in Scotland. *Int J Paediatr Dent* 1997;7:75-80.
13. Llodra JC, Bravo M, Delgado-Rodriguez M, Baca P, Galvez R. Factors influencing the effectiveness of sealants – a meta-analysis. *Community Dent Oral Epidemiol* 1993;21:261-8.
14. Feigal RJ. Sealants and preventive restorations: review of effectiveness and clinical changes for improvement. *Pediatr Dent* 1998;20:85-92.
15. Bhuridej P, Damiano PC, Kuthy RA, Flach SD, Kanellis MJ, Heller KE, et al. Natural history of treatment outcomes of permanent first molars: A study of sealant effectiveness. *J Am Dent Assoc* 2005;136:1265-72.
16. Berry EA 3rd, Ward M. Bond strength of resin composite to air-abraded enamel. *Quintessence Int* 1995;26:559-62.
17. Zyskind D, Zyskind K, Hirschfeld Z, Fuks AB. Effect of etching on leakage of sealants placed after air abrasion. *Pediatr Dent* 1998;20:25-7.
18. Roeder LB, Berry EA 3rd, You C, Powers JM. Bond strength of composite to air-abraded enamel and dentin. *Oper Dent* 1995;20:186-90.
19. Blackwood JA, Dilley DC, Roberts MW, Swift EJ Jr. Evaluation of pumice, fissure enameloplasty and air abrasion on sealant microleakage. *Pediatr Dent* 2002;24:199-203.
20. Manhart J, Huth KC, Chen H, Hickel R. Influence of the pre-treatment of occlusal pits and fissures on the retention of a fissure sealant. *Am J Dent* 2004;17:12-8.
21. Duangthip D, Lussi A. Effects of fissure cleaning methods, drying agents, and fissure morphology on microleakage and penetration ability of sealants in vitro. *Pediatr Dent* 2003;25:527-33.
22. Hatibovic-Kofman S, Butler SA, Sadek H. Microleakage of three sealants following conventional, bur, and air-abrasion preparation of pits and fissures. *Int J Pediatr Dent* 2001;11:409-16.
23. Lupi-Pégurier L, Muller-Bolla M, Bertrand MF, Fradet T, Bolla M. Microleakage of a pit-and-fissure sealant: effect of air-abrasion compared with classical enamel preparations. *J Adhes Dent* 2004;6:43-8.
24. Kanellis MJ, Warren JJ, Levy SM. A comparison of sealant placement techniques and 12-month retention rates. *J Public Health Dent* 2000;60:53-6.
25. Altman DG. *Practical Statistics for Medical Research*. London, UK: Chapman & Hall; 1991.
26. WHO. *Oral Health Surveys. Basic methods*. Geneva: WHO; 1988.
27. Leskinen K, Salo S, Suni J, Larmas M. Comparison of dental health in sealed and non-sealed first permanent molars: 7 years follow-up in practice-based dentistry. *J Dent* 2008;36:27-32.
28. Lussi A. Comparison of different methods for the diagnosis of fissure caries without cavitation. *Caries Res* 1993;27:409-16.
29. Simonsen RJ. Retention and effectiveness of dental sealant after 15 years. *J Am Dent Assoc* 1991;122:34-42.
30. Horowitz HS, Poulsen S. Comparison of blind and non-blind assessments of occlusal sealant retention. *Community*

- Dent Oral Epid 1978;6:24-6.
31. Francis R, Mascarenhas AK, Soparkar P, Al Mutawaa S, Ariga J. Sealant Retention using Rubber Dam and Cotton Roll Isolation. IADR/CADR meeting. Canada, Toronto; 2-5 July 2008; no. 2483.
  32. Weintraub JA. The effectiveness of pit and fissure sealants. *J Public Health Dent* 1989;49(5 Spec no):317-30.
  33. Beiruti N, Frencken JE, van't Hof MA, Taifour D, van Palenstein Helderma W H. Caries-Preventive Effect of a One-Time Application of Composite Resin and Glass Ionomer Sealants after 5 Years. *Caries Res* 2005;40:52-9.
  34. Deery C, Fyffe HE, Nugent ZJ, Nuttall NM, Pitts NB. A proposed method for assessing the quality of sealants - the CCC Sealant Evaluation System. *Community Dent Oral Epidemiol* 2001;29:83-91.
  35. Griffin SO, Oong E, Kohn W, Vidakovic B, Gooch BF. The effectiveness of sealants in managing caries lesions. *J Dent Res* 2008;87:169-74.
  36. Kervanto-Seppälä S, Lavonius E, Pietilä I, Pitkänieniemi J, Meurman JH, Kerosuo E. Comparing the caries-preventive effect of two fissure sealing modalities in public health care: a single application of glass ionomer and a routine resin-based sealant program. A Randomized Split-Mouth Clinical Trial. *Int J Paediatr Dent* 2008; 18: 56-61.
  37. Leskinen K, Ekman A, Oulis C, Forsberg H, Vadiakas G, Larmas M. Comparison of the effectiveness of fissure sealants in Finland, Sweden, and Greece. *Acta Odontol Scand* 2008;66:65-72.
  38. Qualtrough AJE, Satterthwaite JD, Morrow LA, Brunton PA. *Principles of Operative Dentistry*. Blackwell Munksgaard; 2005.
  39. Chong MJ, Seow WK, Purdie DM, Cheng E, Wan V. Visual-tactile examination compared with conventional radiography, digital radiography, and Diagnodent in the diagnosis of occlusal occult caries in extracted premolars. *Pediatr Dent* 2003;25:341-9.
  40. Goel A, Chawla HS, Gauba K, Goyal A. Comparison of validity of DIAGNOdent with conventional methods for detection of occlusal caries in primary molars using the histological gold standard: an in vivo study. *J Indian Soc Pedod Prev Dent* 2009;27:227-34.
  41. Fracaro MS, Seow WK, McAllan LH, Purdie DM. The sensitivity and specificity of clinical assessment compared with bitewing radiography for detection of occlusal dentin caries. *Pediatr Dent* 2001;23:204-10.
  42. Rodrigues J, de Vita TM, Cordeiro R. In vitro evaluation of the influence of air abrasion on detection of occlusal caries lesions in primary teeth. *Pediatr Dent* 2008;30:15-8.
  43. Eliades G, Watts DC, Eliades T, ed. *Dental Hard Tissues and Bonding*. Berlin Heidelberg: Springer-Verlag; 2005.

Received: 05 05 2009

Accepted for publishing: 23 09 2010