

Veneer fracture in implant-supported metal-ceramic restorations. Part I: Overall success rate and impact of occlusal guidance

Tomas Linkevicius, Eugenijus Vladimirovas, Simonas Grybauskas, Algirdas Puisys, Vygandas Rutkunas

SUMMARY

Purpose. The aims of the presented study were to define the fracture rate of implant-supported metal-ceramic restorations delivered in private practice, and to identify if a restoration's contact during eccentric mandible movements has any influence on ceramic fracture rates.

Material and Methods. Within the period from 2005 to 2008, 251 patients, namely 105 men (42%) and 146 women (58%), received 775 dental implants which later were restored with metal-ceramic restorations. Data was gathered and analyzed in the form of a specially-designed electronic questionnaire. In total, 251 patients were rehabilitated with 350 prostheses consisting of 151 single crowns, 208 fixed partial dentures of various extents and 21 full-arch restorations. The method for retention of prostheses included cement-, screw-, or hybrid cement-screw retained prosthetic devices. The patients were recalled and examined for the presence of mechanical complications, namely ceramic fractures. Fractures were distinguished as adhesive or co-adhesive. The follow-up time was registered.

Results. The mean ceramic fracture rate was 6.7%, as fracture occurred in 24 restorations. In the single crown group, the fracture rate was 1.3%, in the fixed partial denture division it was 6.7%, and the full-arch metal-ceramic restorations experienced 38.1% chipping. The mean follow-up period of prostheses was 9.5 months, ranging from 1 to 42 months. The analysis revealed that 66 prostheses had contact in protrusive and/or lateral mandibular movements, constituting 17.4% of all restorations; while 13 restorations had ceramic fractures, composing 19.7% of all guiding prostheses.

Conclusions. Within the limitations of this trial, it can be noted that ceramic veneer fracture rate was 6.7% in 380 restorations, and a conclusion that a restoration's contact during eccentric excursions may significantly enlarge fracture rates can be made.

Key words: implant-supported restorations, occlusal guidance, ceramic fracture, metal-ceramic restorations.

INTRODUCTION

The use of dental implants in everyday practice is rapidly increasing, as patients and dentists become more aware of biological and functional benefits of

this treatment, compared to traditional fixed partial dentures of removable prosthetic appliances [1]. The possibility to restore a missing tooth without damaging the neighbouring ones or escape the inconveniences of acrylic dentures is already occupying the appropriate place among treatment strategies. Therefore, the need of implant prosthodontics is also experiencing continuous growth. Despite the availability of many different laboratory materials, metal-ceramic restorations are commonly used for prosthetic rehabilitation of osseointegrated implants [2]. Zirconium, aluminium or titanium-based restorations seem to be a very promising alternative with many advantages, showing acceptable clinical success rates in short-

¹Institute of Odontology, Faculty of Medicine, Vilnius University, Vilnius, Lithuania

²Vilnius Implantology Center, Vilnius, Lithuania

*Tomas Linkevicius*¹ – D.D.S., Dip Pros, assist. prof.

*Eugenijus Vladimirovas*² – D.D.S.

*Simonas Grybauskas*¹ – D.D.S., MD, MOS RCSEd

*Algirdas Puisys*² – D.D.S.

*Vygandas Rutkunas*¹ – D.D.S., PhD, assoc. prof.

Address correspondence to Dr. Tomas Linkevicius, Institute of Odontology, Faculty of Medicine, Vilnius University, Zalgirio str. 115, LT-08217, Vilnius, Lithuania.

E-mail address: linktomo@gmail.com

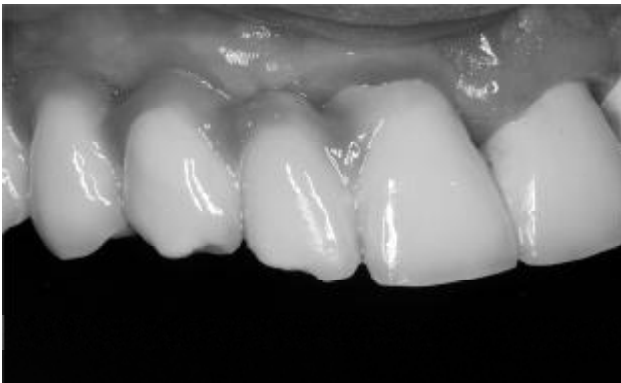

Fig. 1. Fracture of veneering material in implant-supported metal-ceramic restoration

term trials [3, 4]. However, the lack of long-term clinical studies proving enduring reliability of the mentioned materials sometimes may limit their usage in implant prosthodontics.

Depending on the clinical situation, a practitioner can restore implants with single or splinted crowns, fixed partial dentures of various extension and full-arch restorations. The longevity of these constructions has been studied by numerous authors who have reported different success rates. However, one conclusion is common in all clinical trials – metal-ceramic restorations do experience technical complications. They can range up to 4.5% in 5 years [5] or 14% in the period of 10 years [6]. Abutment screw loosening and veneer fracture were reported to be general mechanical problems, the latter being the most common. Sharma reported 13.6 % ceramic fracture [7], which is very similar to the conclusions of Pjetursson et al systematic review that veneer fracture rate of restoration can be up to 14% [8]. In comparison, tooth-supported prostheses may experience only 3.2% of ceramic fracture in the period of 10 years [9, 10]. This difference can be attributed to lack of proprioception and resiliency of implant-supported prostheses. The absence of periodontal ligament makes the crown and its supportive implant relatively immobile, thus prosthetic and abutment materials have to withstand major stress when occlusal load is applied [11]. In addition, it was found that implant-supported restorations may suffer from an 8-time bigger load compared to tooth-borne crowns, as there are no proprioceptors to control the chewing force [12]. Thus, the junction of metal framework and veneering ceramic, which can be considered one of the weakest links in porcelain-fused-to-metal restorations, is constantly experiencing overload and, consequently, may fail. Additional stress may be experienced by restorations if they guide protrusive and/or lateral excursions of mandible, as it was shown by Wie and colleagues [13]. However, there is lack of informa-

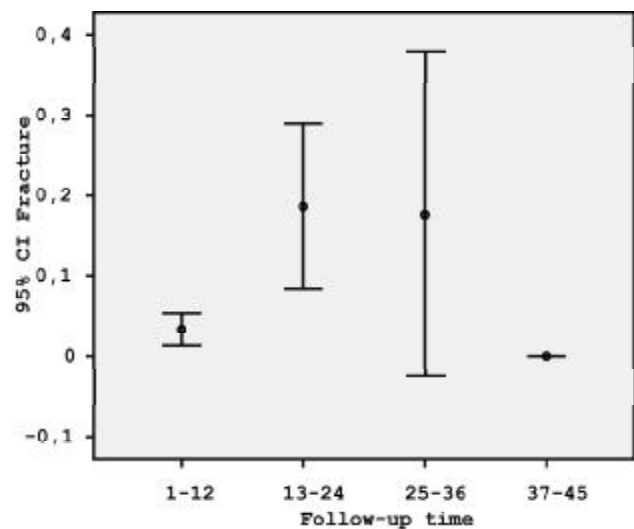


Fig. 2. Ceramic fracture rate dependence on follow-up

tion about the impact of this occlusal guidance on ceramic veneer stability.

Although, coincidentally or not, the absolute majority of studies dealing with implant prosthodontics arise from academic university environment, data from private practice may also provide valuable information. Therefore, the aim of this study was to gather the data about performance of metal-ceramic implant-supported restorations in private practice, analyze it, and compare with the results of other studies. An additional purpose was to identify if a restoration's contact during eccentric mandible movements (guidance) has any influence on ceramic fracture rates.

MATERIAL AND METHODS

The material was collected from the patients who, during period from 2005 to 2008, attended Vilnius Implantology Center (Vilnius, Lithuania) for implant treatment. A special electronic questionnaire was created to register and process the data. After clinical and radiographic examinations, implants were inserted using the submerged or non-submerged method according to individual treatment plans. In total, 251 patients, namely 105 men (42%) and 146 women (58%) with the average age of 42.1 ± 11.3 years (range from 19 to 76 years old), received 775 implants (BioHorizons, Ala, USA) in maxilla and mandible. Following the appropriate healing time, the implants were evaluated according to the success criteria set by Albrektsson et al [14], and a prosthetic phase of treatment was initiated for the successfully osseointegrated fixtures.

Depending on the clinical situation, the implants were restored with single crowns, fixed partial dentures with different amount of units or cross arch re-

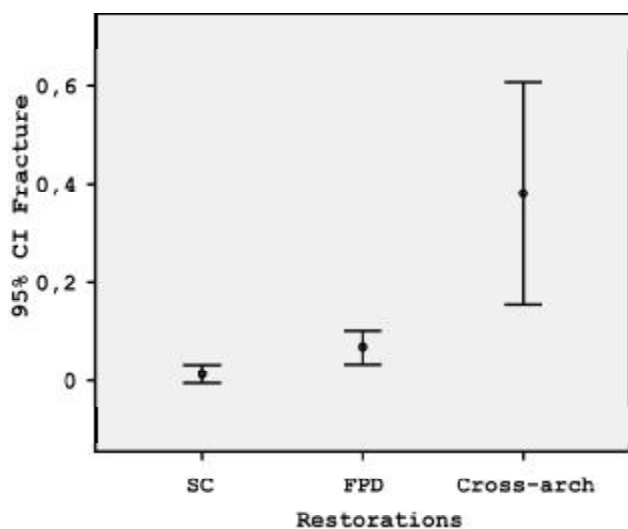


Fig. 3. Fracture rate of different types of prostheses

constructions, using metal-ceramic prostheses. In total, the patients were rehabilitated with 350 prostheses, comprising of 151 single crowns (39.7%), 208 fixed partial dentures (54.7%) and 21 full cross-arch reconstructions (5.6%). Restorations consisted of 975 prosthetic units, namely, 151 units in single crowns, 564 units in fixed partial dentures and 260 units in cross-arch bridges. The retention method of prostheses included cement-, screw-, or hybrid cement-screw retained restorations and fell into proportions as follows: 346 cement-retained restorations, 12 screw-retained prostheses and 22 cement-screw retained restorations. Standard and individually cast abutments were utilized for support of the listed prostheses.

All abutments were secured to implants with a torque of 30 N/cm, using a torque wrench. Glass-ionomer modified with resin (Fuji Plus, GC, Japan) was used as cement for placing cement-retained and cement-screw retained restorations. Screw-retained prostheses were retightened with a torque wrench to 30N/cm one week after initial placement. Occlusal perforations were closed with composite resin, following ceramic etching with hydrofluoric acid, silane and bonding application.

Four different laboratories were involved in the fabrication of metal-ceramic restorations. For fabrication of the frameworks alloy Co-Cr was used as base metal. Different ceramics were used for layering in fabrication of prostheses – GC Initial (GC, Japan), Inspiration (Heimerle-Meule, Germany), Design (Ivoclar, Liechtenstein) and Vita VM7 (Vita Zahnfabrik, Germany). A regular occlusal scheme was applied to all prostheses, meaning, that 12 μ m articulating paper was used for the assessment of contacts, and the restoration had to firmly hold the tape in habitual occlusal position. The restorations

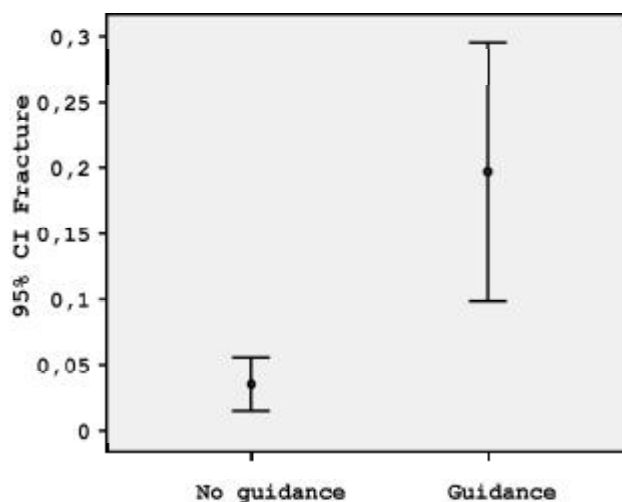


Fig. 4. Occlusal guidance impact on fracture rate

were inspected to ensure that occlusal contacts were not positioned on oblique planes and posterior prostheses did not have contact during eccentric mandible movements. Special attention was devoted to patients with signs of bruxism, as an additional hazard for veneer complications. If a patient had at least 4 signs of parafunction (posterior and anterior dental attrition, abstractions, and occlusal pits), they were attributed to the bruxing group [15]. All the patients included into the study gave informed content to use their data for scientific purposes. Patients were recalled and inspected for the presence of mechanical complications, namely ceramic fractures (Fig. 1). Fractures were distinguished as adhesive or co-adhesive. The follow-up time was registered.

Statistical analysis

SPSS 16 was used for statistical evaluation of the obtained data. First, descriptive analysis was performed. Cross tabulation charts were used to describe the distribution of the variable. Chi-square test was utilized to determine differences between groups. To visualize these differences, error bar charts were used. Significance level was set to $P=0.05$ with a confidence interval of 95%.

RESULTS

The statistical analysis included 350 porcelain-fused-to-metal restorations placed in 251 patients. The mean follow-up period of prostheses was 9.5 months, ranging from 1 to 42 months. According to the length of the follow-up period, all the restorations were divided into 4 groups: up to 1 year, 1-2 years, 2-3 years and over 3 years (Table 1). There was a significant variation of failure rate between the first and the second year of service (Fig. 2) and this difference was

statistically significant ($\chi^2=23,605$; $df=3$; $p=0,000$). The mean ceramic fracture rate was 6.7%, as fracture occurred in 24 restorations. In the single crown group fracture rate was 1.3%, in the fixed partial denture division – 6.7%, and the full-arch metal-ceramic restorations experienced 38.1% chipping. The relation of ceramic chipping rate to overall amount of prosthetic devices may be seen in Table 2. The chipping rate to number of prosthetic units in 3 groups of restorations is presented in Table 3. The difference between the full-arch restorations and 2 other groups was found to be statistically significant ($\chi^2=42,263$; $df=2$; $p=0,000$) and can be seen in Fig. 3.

The adhesive complication was registered in 6 cases, which constitutes 25% of all fractures and 1.6% of all restorations; while co-adhesive chipping occurred in 18 occasions, composing 75% of fractures and, respectively, 4.7% of prostheses (Table 4).

The analysis revealed that 66 prostheses had contact in protrusive and/or lateral mandibular movements, composing 17.4% of all restorations; while 13 restorations had ceramic fractures, composing 19.7% of all guiding prostheses. It was concluded that 54.2% (13 out of 24) of all failures occurred in guiding restorations (Table 5). Consequently, contact during eccentric mandibular movements significantly increases the possibility of veneer complications ($\chi^2=24,171$; $df=1$; $p=0,000$). This dependence is depicted in Fig. 4.

DISCUSSION

The purpose of this retrospective study was to evaluate the performance of implant-supported metal-ceramic restorations delivered in private practice. Specifically, the study aimed at identifying fracture rates of veneering material and the influence of eccentric mandible movements, within different follow-up periods, on the dynamics of these changes. The major findings of this study show that ceramic chipping can reach up to 6.7% in the period up to 3 years. This is similar to the outcome of the study by Jung et al, reporting 4.5% complication rate after a 5-year follow-

Table 1. Distribution of restorations by period of follow-up

Follow-up groups	Frequency	Percent	Valid Percent
Valid 1-12	301	79.2	79.2
13-24	59	15.5	15.5
25-36	17	4.5	4.5
37-45	3	0.8	0.8
Total	380	100.0	100.0

up [16]. However, it must be pointed out that in the current study the mean observation period was only 9.5 months, and the majority of the restorations were followed-up for 1-2 years. Therefore, it would be interesting to compare these results after a more extended surveillance period, which would also bring more objectivity into the study.

The complication occurrence was partly dependant on the follow-up period, as the restorations observed for two years encountered significantly different amount of fractures compared to those observed for 1 year. Interestingly, the prostheses maintained for 3 years did not experience additional amount of complications. This can be explained by the fact that only a small amount of the restorations fell in this category of observation, and therefore, no definitive conclusions can be drawn. Generally, studies show that the rate of complication tends to increase, as the follow-up period is extending [17, 18].

Another interesting finding was different distribution of the failure rates among the 3 groups of restorations. The cross-arch metal-ceramic implant-supported prostheses experienced utmost ceramic fractures, ranging up to 38.1%. The single crowns and fixed partial dentures had significantly lower complication occurrence. This can be attributed to increased loads and dramatically compromised nervous feedback to control chewing forces in patients with full-mouth implant-borne prosthetic rehabilitations. Some studies have shown that even complete dentures do perform a better oral sensory function than restorations, supported by dental implants [19, 20]. Thus, porcelain-fused-to-metal prostheses on implants should be used very cautiously in restoring the masti-

Table 2. Types of restorations

			Restorations			Total
			SC	FPD	Cross-arch	
Chipping	O.K.	Count	149	194	13	356
		% within Restorations	98.7%	93.3%	61.9%	93.7%
		% of Total	39.2%	51.1%	3.4%	93.7%
	Chipped	Count	2	14	8	24
		% within Restorations	1.3%	6.7%	38.1%	6.3%
		% of Total	.5%	3.7%	2.1%	6.3%
Total		Count	151	208	21	380
		% within Restorations	100.0%	100.0%	100.0%	100.0%
		% of Total	39.7%	54.7%	5.5%	100.0%

Table 3. Ceramic fracture rate of restorations with different amount of units

			Chipping		Total
			O.K.	Chipped	
No of Units	1 unit	Count	149	2	151
		% within Chipping	41.9%	8.3%	39.7%
		% of Total	39.2%	0.5%	39.7%
	2 unit	Count	101	9	110
		% within Chipping	28.4%	37.5%	28.9%
		% of Total	26.6%	2.4%	28.9%
	3 unit	Count	66	2	68
		% within Chipping	18.5%	8.3%	17.9%
		% of Total	17.4%	0.5%	17.9%
	4 unit	Count	17	3	20
		% within Chipping	4.8%	12.5%	5.3%
		% of Total	4.5%	0.8%	5.3%
	5 unit	Count	6	0	6
		% within Chipping	1.7%	0.0%	1.6%
		% of Total	1.6%	0.0%	1.6%
	6 unit	Count	1	0	1
		% within Chipping	0.3%	0.0%	0.3%
		% of Total	0.3%	0.0%	0.3%
	7 unit	Count	1	0	1
		% within Chipping	0.3%	0.0%	0.3%
		% of Total	0.3%	0.0%	0.3%
	8 unit	Count	1	0	1
		% within Chipping	0.3%	0.0%	0.3%
		% of Total	0.3%	0.0%	0.3%
	9 unit	Count	1	0	1
		% within Chipping	0.3%	0.0%	0.3%
		% of Total	0.3%	0.0%	0.3%
	10 unit	Count	2	0	2
		% within Chipping	0.6%	0.0%	0.5%
		% of Total	0.5%	0.0%	0.5%
	12 unit	Count	8	5	13
		% within Chipping	2.2%	20.8%	3.4%
		% of Total	2.1%	1.3%	3.4%
	14 unit	Count	3	3	6
		% within Chipping	0.8%	12.5%	1.6%
		% of Total	0.8%	0.8%	1.6%
Total		Count	356	24	380
		% within Chipping	100.0%	100.0%	100.0%
		% of Total	93.7%	6.3%	100.0%

Table 4. Descriptive analysis of type of ceramic failure

		Frequency	Percent	Valid Percent	Cumulative Percent
Valid	Coadhesive	18	4.7	75.0	75.0
	Adhesive	6	1.6	25.0	100.0
	Total	24	6.3	100.0	
Missing	No chipping	356	93.7		
Total		330	100.0		

atory function in edentulous patients, and an acrylic nightguard should be an inseparable part of such treatment. In addition, it has been suggested to employ hybrid fixed dentures (metal framework and acrylic teeth) for implant restorations, especially if implants oppose each other in both dental arches. However, aesthetic and material wear concerns could arise if this kind of treatment was applied [21].

The attention of a reader may focus on very low percent (1.3%) of prosthetic complications in single

implants group. This can be attributed to easier achievable passive fit and better margin adaptation of frameworks of single crowns, compared to fixed partial dentures or full-arch restorations. Therefore, this kind of approach can be considered a valuable alternative to splinted crowns on implants.

Ceramic fracture type was also in the scope of the author's interest. Generally, two types of veneer complications are distinguished. Adhesive failure is diagnosed if ceramic fracture denudes supporting metal framework, and co-adhesive failure is identified when complications occur within veneering material, without involvement of the frame [22]. The majority of the failures in the current study were of co-adhesive kind, although no statistically significant differences between both types of complications were noted. Therefore, it may be concluded that the laboratories developed a proper bond between ceramic and metal. On the other hand, co-adhesive fractures may indicate the presence of insufficiently supported ceramic.

Another purpose of this retrospective evaluation was to define if occlusal contact of the implant restoration during eccentric mandibular movements is a significant factor in ceramic fracture aetiology. It has been suggested that non-axial load may be harmful to implant-supported prostheses and should be avoided whenever possible [23, 24]. Many clinical and animal trials have proved that oblique force, which is generated in the mouth, is not a threat to osseointegrated interface between bone and implant [25, 26, 27], how-

ever, the risk of fatigue ceramic fractures is relevant. Tornbjorner and Fransson have shown that indeed protrusive and lateral excursions can generate excessive functional loads to guiding restorations, and fractures of materials may be one of accompanying complications [28, 29]. It is well-known that veneering porcelain should not exceed 2 mm in height to prevent iatrogenic ceramic fractures [30]. This status quo between metal framework and overlaying porcelain should always be kept, especially,

if restoration takes part in guiding eccentric mandibular movements.

The results of the current study indicate that in this particular patient sample, occlusal guidance can be viewed as an additional hazard for the loss of prosthesis integrity, as more than a half of all the fractured restorations did have guiding contact. A more detailed examination defined that almost 20% of all the guiding implant crowns had ceramic chipping of various extent. Literature search did not find any clinical implant-related study discussing the subject matter. Data from similar studies allows hypothesizing that veneering material complications of excursion-bearing crowns in implant dentistry may be more frequent in comparison to teeth-supported prosthetic devices. Thus, it can be recommended to avoid implant-supported restorations as guiding abutments, whenever it is possible to achieve it.

The metal-ceramic restorations analyzed in this trial were prescribed a regular occlusion scheme. Articulating paper of 12 μ m was used to assess the strength of occlusal contacts. Some authors have proposed to use the concept of implant protected occlusion [31]. It embodies the protection of underlying implant from stresses during function or

parafunction. The protection is ensured by leaving implant-supported restoration slightly out of occlusion, approximately 30 μ m, and this way reducing the load and increasing the protection of implant-bone interface. However, there is no evidence that implant protected occlusion actually prolongs the service time of implants and their supported restoration or reduces the rate of biological and technical complications [32, 33].

CONCLUSIONS

Within the limitations of this retrospective trial, the following conclusions can be made: ceramic veneer fracture rate was 6.7% in 380 restorations; full-arch metal-ceramic prostheses increased the risk of this particular complication, while a single implant-supported prosthesis may be preferable treatment of choice, if clinical situation is favourable; a restoration's contact during eccentric excursions may significantly enlarge fracture rates. Finally, it can be added that more clinical trials are needed for clearer identification of the factors having influence on porcelain fractures of implant-supported metal-ceramic restorations.

REFERENCES

- Jokstad A, Braegger U, Brunski JB, Carr AB, Naert I, Wennerberg A. Quality of dental implants. *Int Dent J* 2003;53:409-43.
- Preiskel HW, Tsolka P. Cement- and screw-retained implant-supported prostheses: up to 10 years of follow-up of a new design. *Int J Oral Maxillofac Implants* 2004;19:87-91.
- Jemt T, Henry P, Linden B, Naert I, Weber H, Wendelhag I. Implant-supported laser-welded titanium and conventional cast frameworks in the partially edentulous jaw: a 5-year prospective multicenter study. *Int J Prosthodont* 2003;16:415-21.
- Schiroli G. Single-tooth implant restorations in the esthetic zone with PureForm ceramic crowns: 3 case reports. *J Oral Implantol* 2004;30:358-63.
- Jung RE, Pjetursson BE, Glauser R, Zembic A, Zwahlen M, Lang NP. A systematic review of the 5-year survival and complication rates of implant-supported single crowns. *Clin Oral Implants Res* 2008;19:119-30.
- Pjetursson BE, Tan K, Lang NP, Bragger U, Egger M, Zwahlen M. A systematic review of the survival and complication rates of fixed partial dentures (FPDs) after an observation period of at least 5 years. *Clin Oral Implants Res* 2004;15:625-42.
- Sharma P. Implant supported fixed partial dentures survival rate high, but biological and technical complications common. *Evid Based Dent* 2005;6:72-3.
- Pjetursson BE, Tan K, Lang NP, Bragger U, Egger M, Zwahlen M. A systematic review of the survival and complication rates of fixed partial dentures (FPDs) after an observation period of at least 5 years. *Clin Oral Implants Res* 2004;15:625-42.
- Tan K, Pjetursson BE, Lang NP, Chan ES. A systematic review of the survival and complication rates of fixed partial dentures (FPDs) after an observation period of at least 5 years. *Clin Oral Implants Res* 2004;15:654-66.
- Sharma P. 90% of fixed partial dentures survive 5 years. How long do conventional fixed partial dentures (FPDs) survive and how frequently do complications occur? *Evid Based Dent* 2005;6:74-5.
- Schulte W. Implants and the periodontium. *Int Dent J* 1995;45:16-26.
- Hammerle CH, Wagner D, Bragger U, Lussi A, Karayiannis A, Joss A, Lang NP. Threshold of tactile sensitivity perceived with dental endosseous implants and natural teeth. *Clin Oral Implants Res* 1995;6:83-90.
- Wie H. Registration of localization, occlusion and occluding materials for failing screw joints in the Branemark implant system. *Clin Oral Implants Res* 1995;6:47-53.
- Albrektsson T, Zarb G, Worthington P, Eriksson AR. The long-term efficacy of currently used dental implants: a review and proposed criteria of success. *Int J Oral Maxillofac Implants* 1986;1:11-25.
- Tsigos N, Tortopidis D, Hatzikyriakos A, Menexes G. Association between self-reported bruxism activity and occurrence of dental attrition, abfraction, and occlusal pits on natural teeth. *J Prosthet Dent* 2008;100:41-6.
- Jung RE, Pjetursson BE, Glauser R, Zembic A, Zwahlen M, Lang NP. A systematic review of the 5-year survival and complication rates of implant-supported single crowns. *Clin Oral Implants Res* 2008;19:119-30.
- De BH, Van MG, De MN, Van den BL, De BJ. A 20-year retrospective survival study of fixed partial dentures. *Int J Prosthodont* 2006;19:143-53.
- Attard NJ, Zarb GA. Long-term treatment outcomes in edentulous patients with implant-fixed prostheses: the Toronto study. *Int J Prosthodont* 2004;17:417-24.
- Jang KS, Kim YS. Comparison of oral sensory function in complete denture and implant-supported prosthesis wearers. *J Oral Rehabil* 2001;28:220-5.
- Jacobs R, van SD. Comparative evaluation of the oral tactile

- function by means of teeth or implant-supported prostheses. *Clin Oral Implants Res* 1991;2:75-80.
21. Abbo B, Razzoog ME. A procedure for repairing a fixed implant-supported complete denture. *J Prosthet Dent* 2005;93:588-9.
 22. dos Santos JG, Fonseca RG, Adabo GL, dos Santos Cruz CA. Shear bond strength of metal-ceramic repair systems. *J Prosthet Dent* 2006;96:165-73.
 23. Rangert B, Jemt T, Jorneus L. Forces and moments on Branemark implants. *Int J Oral Maxillofac Implants* 1989;4:241-7.
 24. Rangert B, Sennerby L, Meredith N, Brunski J. Design, maintenance and biomechanical considerations in implant placement. *Dent Update* 1997;24:416-20.
 25. Berglundh T, Abrahamsson I, Lindhe J. Bone reactions to longstanding functional load at implants: an experimental study in dogs. *J Clin Periodontol* 2005; 32:925-32.
 26. Heitz-Mayfield LJ, Schmid B, Weigel C, Gerber S, Bosshardt DD, Jonsson J, Lang NP, Jonsson J. Does excessive occlusal load affect osseointegration? An experimental study in the dog. *Clin Oral Implants Res* 2004;15:259-68.
 27. Barboza EP, Caula AL, Carvalho WR. Crestal bone loss around submerged and exposed unloaded dental implants: a radiographic and microbiological descriptive study. *Implant Dent* 2002;11:162-9.
 28. Torbjörner A, Fransson B. A literature review on the prosthetic treatment of structurally compromised teeth. *Int J Prosthodont* 2004;17:369-76.
 29. Torbjörner A, Fransson B. Biomechanical aspects of prosthetic treatment of structurally compromised teeth. *Int J Prosthodont* 2004;17:135-41.
 30. Rosenstiel SF, Land MF, Fujimoto J. Contemporary fixed prosthodontics. 2nd ed ed. St. Louis: Mosby; 1995.
 31. Misch CE, Bidez MW. Implant-protected occlusion: a biomechanical rationale. *Compendium* 1994;15:1330,1332,1334.
 32. Taylor TD, Belser U, Mericske-Stern R. Prosthodontic considerations. *Clin Oral Implants Res* 2000; 11(Suppl 1):101-7.
 33. Kim Y, Oh TJ, Misch CE, Wang HL. Occlusal considerations in implant therapy: clinical guidelines with biomechanical rationale. *Clin Oral Implants Res* 2005;16: 26-35.

Received: 15 07 2008

Accepted for publishing: 19 12 2008