

5 year experience with lower lip cancer

Egils Kornevs, Andrejs Skagers, Juris Tars, Andris Bigestans, Gunars Lauskis, Olafs Libermanis

SUMMARY

Retrospective study of 189 cases of lower lip cancer treated from 1996 - 2000 is done. There were 69% males and 31% females. Median age was 66.8 years. 84.4% of patients were with tumors stage I - II. Surgical treatment was performed in 83.6 % of patients . In all operated cases was squamous cell carcinoma as verrucous tumor in 17.4 %, as exophytic in 46% and as ulcerative in 36.6%. There were different methods of local excision, primary reconstruction and neck dissection depending from stage.

In the patient group with clinically negative neck at the first attendance (170 patients) delayed cervical metastases developed in 6 patients (3.5%). Recurrence at the primary site developed in 11.3 % of patients and was associated with large tumor size and low cancer differentiation. Survival rate at 5-year follow-up was 95% for patients with I stage, 89.7% for II stage and 37% for III and IV stage patients or mean for all group 83.7%. Diagnosis and treatment of actinic cheilitis also is discussed.

Key words: lip, cancer, surgery, outcomes

INTRODUCTION

Cancer of the lip is relatively common among malignancies of the head and neck region, accounting for 12% of all head and neck cancers, excluding nonmelanoma skin cancer and for approximately one quarter of oral cavity cancers. 95% occur on the lower lip. Although this form of cancer is generally readily curable compared with malignancies at other head and neck sites, regional metastases, local recurrence, and even death from this disease may occasionally occur (8, 11-13) (Fig. 1).

Most commonly found in fair - complexioned, white males in their sixth decade of life. Often found in those persons having outdoor occupations with prolonged solar radiation. Other associated factors that have a less certain role in the etiology of lip carcinoma are tobacco smoking, viruses, poor oral hygiene, alcoholism. The etiology of the disease is far from established. A range of environmental and host factors has been identified to explain the etiopathogenesis of squamous cell carcinoma of the lip. However, the definitive pathogenic pathway remains unclear. Carcinogen-

esis does not seem to be limited to a single agent, but rather to a complex multistep process of interactions between putative risk factors (2) (Fig. 2).

The epidemiology of lip cancer supports the proposal that the lip should be considered as a distinct cancer site, rather than being included with other forms of intraoral cancer (4). Although the lips play a role in deglutition and articulation, one must remember that the major criterion for successful lip reconstruction is oral competence.

MATERIAL AND METHODS

The retrospective study included 189 patients with lower lip carcinoma treated in Latvian Oncological Center from 1996 to 2000. There were 131 males (69%) and 58 females (31%) with a median age of 66.8 years (range 33-89 years). The majority of cases were stage I and stage II tumours (158 patients; 84.4%). 27 patients were in stage III and IV. In 4 cases stage was unknown.

Actinic exposure appears to be an etiologic factor in squamous cell carcinoma of the lower lip, as evident by such risk factors as occupation and geographic location. The history of the patients revealed liver disease associated to alcohol consumption in 30.4% of cases and tobacco used in any form in 78.6%. As regards solar exposure, 53.1% of the men referred open-air professional activities, while 90% of the women presented important solar exposure. The most frequent clinical manifestations were bleeding and the presence of leukoplakia patches; pain was reported in only 16% of cases. Over 40% of the patients were asymptomatic. The location of the lesions of actinic cheilitis was in all cases on the lower lip. Actinic cheilitis appeared in three forms; white non-ulcerated lesions (29%), erosions or ulcers of the lip (48%), mixed white and erosive (23%). The histopathologic characteristics included increased thickness of keratin layer, alterations of the thickness of spinous cell layer, epithelial dysplasia, connective tissue changes, perivascular inflammation and basophilic changes of connective tissue.

¹Department of Oral and maxillofacial Surgery Riga Stradins University, Latvia.

²Department of Head and Neck Surgery Latvian Oncological center

³Latvian Center of Plastic and Reconstructive Microsurgery

Egils Kornevs¹ - D.D.S., Dr.hab.med., assoc. professor, Department of Oral and maxillofacial Surgery Riga Stradins University, Latvia.

Andrejs Skagers¹ - M.D., Dr.hab.med., profesor, Head of Department of Oral and Maxillofacial Surgery Riga Stradins University, Latvia.

Juris Tars² - M.D., Head of Department of Head and Neck Surgery Latvian Oncological center.

Andris Bigestans¹ - M.D., D.D.S., Lecturer, Department of Oral and maxillofacial Surgery Riga Stradins University, Latvia.

Gunars Lauskis¹ - M.D., D.D.S., Lecturer, Department of Oral and maxillofacial Surgery Riga Stradins University, Latvia.

Olafs Libermanis³ - Surgeon, Latvian Center of Plastic and Reconstructive Microsurgery.

Address correspondence to Prof. Egils Kornevs, Institute of Stomatology, Dzirciema str. 20, Riga, Latvia, LV-1007.
E-mail : kornevsegils@inbox.lv

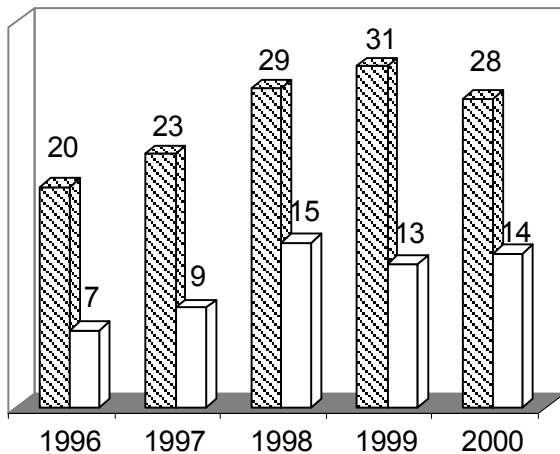


Fig. 1. Incidence of the lip cancer in Dept. Head Neck Surg Latvian Oncological Center

In 11 cases (16.9%) the presence of squamous cell carcinoma was observed. This case-series highlights varied clinical presentation of actinic cheilitis among whom a high proportion developed squamous cell carcinoma.

Vermilionectomy is the recommended treatment for actinic cheilitis. Operation usually performed on the lower lip in which a part or all of the vermilion surface of the lip is excised. This procedure should be used for premalignant lesions of the lip such as severe actinic cheilitis and leukoplakia with atypia.

Clinically the SCC is seen initially in a wide variety of forms - ulcer, wart, sore, scab, blister, fissure, crusting, sunburn, tumor, knot, trauma. The differential diagnosis will include some precursors of squamous cell carcinoma as the chronic actinic changes of hyperkeratosis, verruca vulgaris, keratoacanthoma and leukoplakia. Three gross types of SCC have been observed: verrucous (33 patients; 17.4%), exophytic (87 patients; 46%) and ulcerative. (69 patients; 36.6%). In addition to squamous cell carcinoma, other histologic varieties arising from the mucosa of the lip are: basal cell carcinoma, melanoma and salivary gland tumors. The latter three are rare.

The usual location on the lower lip is halfway between the commissure and the midline. The lesions at the commissure appear to have a poorer prognosis than do the other lower lip lesions. The vermilion border of the lower lip is a frequent location of squamous cell carcinoma (SCC), but it is rarely mentioned of basal cell carcinomas (BCCs). In 5 cases, the neoplasm involved either mainly or exclusively the vermilion border of either the lower (2 cases) or the upper (3 case) lip (Fig. 3).

The treatment of carcinoma of the lower lip is primarily surgical although results for surgery and radiotherapy for smaller lesions are similar. 59 patients with squamous cell carcinoma of the lower lip were treated by irradiation. There were 24 T1, 26 T2, 6 T3 and 3 T4 with 56 N0, 2 N1 and 1 N2 patients. At presentation, regional lymph nodes were clinically negative in all but 3 patients. During follow-up, regional lymph node metastases at level I (submental and submandibular groups) occurred in 3 out of 24 (12.5%) patients with stage I, in 2 out of 26 (7.6%) patients with stage II tumors and in 1 out of 6 patients with stage III tumors. All

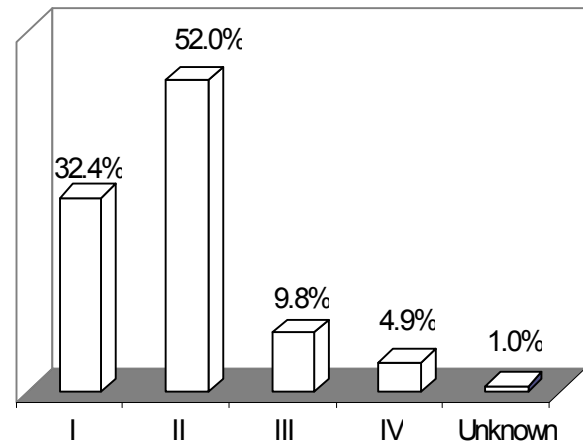


Fig. 2. Distribution of lower lip cancer according to stage in Dept. Head Neck Surg Latvian Oncological Center

these 6 patients underwent therapeutic neck dissection, followed by radiotherapy in 5 cases.

The selection of the most appropriate procedure for the removal of lip carcinoma obviously depends on the clinical assessment. 4 patients refused from offered treatment. Any operation for lip cancer should have as the primary goal complete, en bloc removal of the tumor with normal tissue margins. Important but secondary considerations are the preservation or restoration of lip function and cosmesis. Although varied recommendations for margins may be found in the literature, in general, a minimum of 8 to 10 mm of normal tissue margin should be taken with the lesion in order to adequately remove the tumor (1, 3, 6). A 3 mm margin with excision of early SCCLL seems to be appropriate, if the margins are controlled by systematic use of frozen-section analysis (3). Primary lesions measuring 1.5 cm or less can be excised with a margin of 5 to 7 mm or a total resection of approximately one third of the lower lip and the edges coapted without undue tension (5). Resection is accomplished most efficaciously by "V" excision and primary closure. If the excision or tip of the "V" will cross the mental crease, a more acceptable scar is obtained by modifying the "V" into a "W", permitting transverse closure of the inferior portion at the mental crease. Both the V and W forms of full-thickness excisions can be satisfactorily closed primarily if the resultant defect is no more than 30% to 40% of the length of the lip. Careful attention should be directed to repair of the orbicularis muscle for reconstruction of the oral sphincter. As mentioned before, Vermilionectomy was performed to 11 patients. Reconstruction of vermilionectomy defects was usually done using a mucosal advancement flap. "V" or "W" excision were performed to 25 patients. Defects of 30 to 65%. Transfer of upper lip tissue (lip-switch) pedicled on the labial artery can be accomplished by the Abbe technique (1889), preserving the oral commissure, or rotated around the commissure by the Estlander method (1872). Abbe and Estlander cross-lip flaps have been described and designed as a full-thickness flap to reconstruct a full-thickness excisional defect (10). Abbe flap was performed to 30 patients Estlander method to 16 patients. According to J.

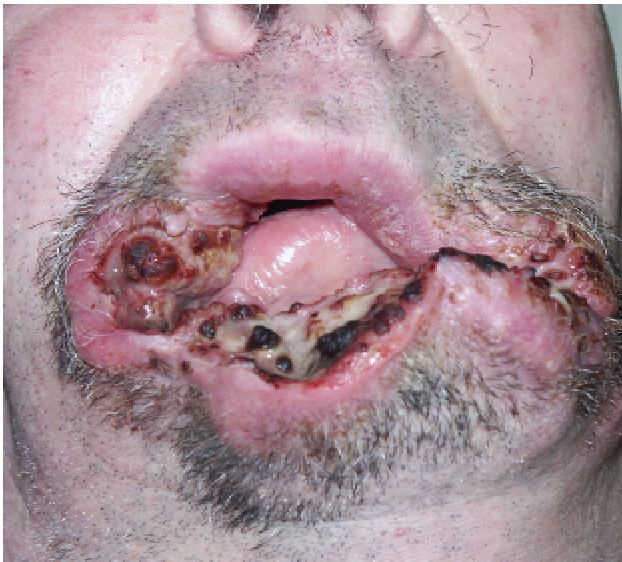

Fig. 3. Advanced cancer of lower lip

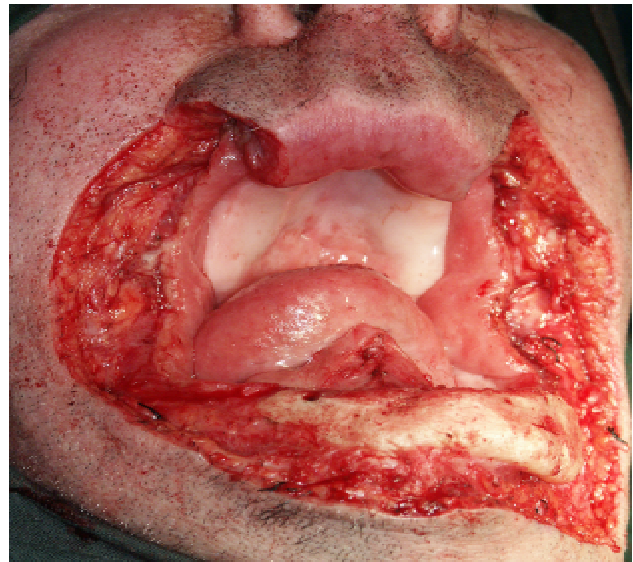


Fig. 4. Defect after resection

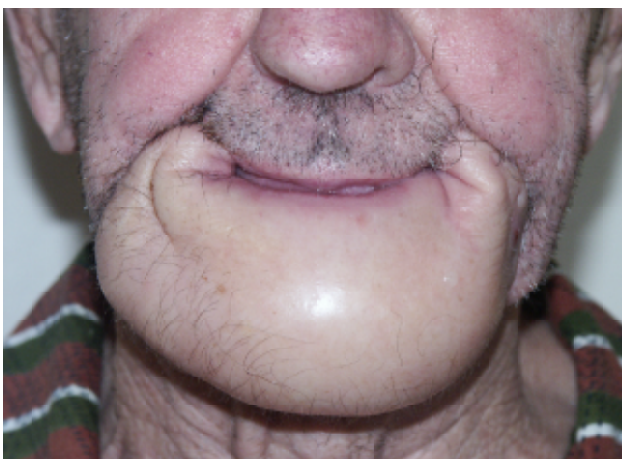

Fig. 5. 3 month after reconstruction with radial forearm flap

Liu modified labial tissue sliding flaps for repairing lower lip defects were used in 15 cases (10). 3 patients were treated with the bilateral symmetrical stair-case technique since their lesions were located medially, while 7 were treated with the bilateral method using two asymmetrical flaps because their lesions were in paramedian position but larger than 2cm. 1 patient required a unilateral flap. (Stair-case technique – 11 patients). The cases classified as T3 (Defects of 65 to 80 per cent) in which the lesion required resection of more than 65% of the lip, were treated with the Bernard-Freeman-Fries technique (10). For defects of this magnitude, about 1,5 cm of lower lip is retained, and it is a challenge to accomplish an end result that meets the criteria of successful reconstruction. Major defects of the lower lip have been repaired in many ways. Of these, some employed flaps from the chin, cheek or upper lip. Some of these procedures employed flaps without regard for the facial grooves or landmarks. Some methods required incisions through nerves supplying the orbicularis oris and the flaps used for the lower lip reconstruction. A widely used technique is the advancement of cheek tissue by the Webster - Bernard approach. Although the initial result obtained may be satisfactory, the

continued chronic tension of the closure has frequently culminated in a tight lower lip that functioned poorly.

A more satisfactory procedure for defects of this magnitude has been the Karapandzic lip rotation, although a microstomia is inevitable. Microstomia is particularly disabling for edentulous patients if they are unable to insert dentures through the microstomia. One compromise may be to reconstruct with the Karapandzic technique, accept the microstomia temporarily, allow the tissues to stretch with time and use, and return with a lip - switch procedure to enlarge the oral opening. Unilateral Bernard technique we have used in 2 patients, bilateral in 8 patients. Total resection of the lip, defects larger than 80 to 85 per cent of the lower lip require essentially total resection. If the lesions is large and infiltrative, that is T3, with invasion of chin, a full - thickness (including mucosa), inferiorly based nasolabial flap or bilateral flaps can be used. A massive resection of the lip, chin, and mandible must be reconstructed with distant flaps and requires reconstruction of the lower lip as a separate unit. Unilateral inferiorly based nasolabial flap we have used in 5 patients, bilateral in 2 patients. There are a lot of techniques that have been reported for total lower lip reconstruction. It is believed that the radial forearm flap is the most suitable technique for lower lip and chin reconstruction after tumor excision so as to achieve better shape and functional results. We have used radial forearm free flap in 1 patient (Fig. 4, 5).

Management of regional lymph nodes in carcinoma of the lower lip remains a subject of controversy (7, 11). In contrast to SCC of the oral cavities, carcinoma of the lower lip has a much lower predilection for regional spread. Yet most of the mortality is the result of uncontrolled disease in the neck. For lower lip carcinoma, an incidence of 15% of cervical lymph node metastasis at presentation is generally accepted. This is an argument in favour of an expectant approach. At presentation, regional lymph nodes were clinically positive in 12 patients from 126 treated surgically. So an incidence 8.1% of cervical lymph node metastasis at presentation was determined in our study.

11 patients of these underwent suprahyoid neck dissection (SHD), 5 of them bilateral, in 4 patients radical

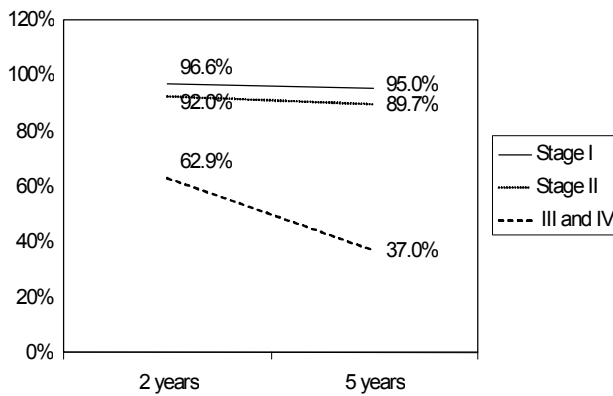


Fig. 6. Graphic picture Determinate survival rates

neck dissection was performed in continuity with the resection of the cancer of the lip. Cervical lymph node metastases in these patients was proven microscopically in 84% of cases.

RESULTS

Out of the patients attending the 2-year follow-up 11% developed a clinically positive neck.

In the patient group with clinically negative neck at the first attendance (170 patients), in the follow - up delayed cervical lymph node metastases developed in 6 patients (3.5%) during the first 6 month, a total of 9 patients (5.2%) within 1 year and a total of 12 patients (7%) within 2 years of follow - up. All the 12 patients who developed a clinically positive neck sooner or later underwent a therapeutic neck dissection. In 6 cases SHD was carried out, in 3 cases (2 bilateral) modified functional neck dissection (up to IV and V level) and radical classical neck dissection in 3 patients. Cervical lymph node metastases was proven in 10 cases (83.3 %). No cases had levels IV and V involved with node metastasis, either clinically or pathologically. In 11 cases cervical metastasis developed when the size of primary tumor was above 3 cm, in 1 case when the size of primary tumor corresponded to T1. In 9 cases in pathological examination were defined high grade tumor.

Recurrence of disease at the primary site developed in 11.3% of the patients reviewed and was strongly associated with large tumor size and poor differentiation. In 60 patients with T1 tumors, recurrences developed in 2 patients (3.3%), in 98 patients with T2 tumors - in 6 patients (6.1%), in 18 patients with T3 - in 7 patients (38.8%), in 9 patients with T4 tumors - in 3 patients. Recurrence of disease after curative treatment were observed in both: at the primary site and in the neck in 3 patients.

The specific lip subsite of involvement appears to influence the chance of local recurrence of lip cancer, the highest risk being associated with lesions of the commissure and the lowest with lower lip lesions.

Recurrence in the lip is best managed with aggressive surgical resection using some form of intraoperative margin assessment to ensure, as completely as possible, the complete clearance of the recurrent tumor. Elective complete neck dissection has been recommended and certainly should be considered because up to one fourth of these patients have occult cervical lymph node metastases.

Surgical management of local recurrences of lip cancer is successful in 75% to 85% of cases. The salvage rate is considerably less with both local and regional lymph node recurrence.

The determinate survival rate was found to be 95% at 5-year follow-up for in patients with I stage tumors, 89.7% in patients with II stage tumors, 37% for III and IV stage tumors. The determinate mean survival rate was found to be 83.7% at 5-year follow-up (Fig. 6).

Like head and neck cancer at other sites, the clinical stage at presentation is the single most important factor affecting the chance of achieving 2-year and 5-year disease-free survival.

CONCLUSIONS

Small lesions are associated with very good chance for cure regardless of the treatment modality used (radiation therapy or surgery). An increase in delayed metastases was observed in patients with tumors greater than 3 cm, but the proportion is not great enough to justify elective neck dissections. The results suggest that suprahyoid neck dissection could be the therapeutic option for patients with clinically positive necks.

REFERENCES

- Breuninger H, Holzschuh J, Schaumburg Lever G, Schippert W, Horny HP. Desmoplastic squamous epithelial carcinoma of the skin and lower lip. A morphologic entity with great risk of metastasis and recurrence. *Hautarzt* 1998; 49(2): 104-8
- de Visscher JG, van der Waal I. Etiology of cancer of the lip. A review. *Int J Oral Maxillofac Surg* 1998; 27(3): 199-203.
- de Visscher JG. Surgical margins for resection of squamous cell carcinoma of the lower lip. *Int J Oral Maxillofac Surg* 2002; 31: 154-7.
- Jovanovic A, Schulten EA, Kostense PJ, Snow GB, van der Waal I. Squamous cell carcinoma of the lip and oral cavity in The Netherlands; an epidemiological study of 740 patients. *J Craniomaxillofac Surg* 1993; 21(4):149-52.
- Hirshowitz B. The double-V excision for better repair of lower lip defects. *Plast Reconstr Surg* 1972; 50(2):153-9.
- Hjortdal O, Naess A, Berner A. Squamous cell carcinomas of the lower lip. *J Craniomaxillofac Surg* 1995; 23(1):34-7.
- Koc C, Akyol MU, Celikkanat S, Cekic A, Ozdem C. Role of suprahyoid neck dissection in the treatment of squamous cell carcinoma of the lower lip. *Ann Otol Rhinol Laryngol* 1997; 106(9): 787-9.
- Nuutinen J, Karja J. Local and distant metastases in patients with surgically treated squamous cell carcinoma of the lip. *Clin Otolaryngol* 1981; 6(6): 415-9.
- Pitkanen J, Lahti A, Sundell B. Carcinoma of the lip. A retrospective study of 70 patients. *Scand J Plast Reconstr Surg* 1985; 19(3): 289-94.
- Schubert J. Variations in lower lip reconstruction. *J Oral Maxillofac Surg*. 2001 Apr;59(4):399-402.
- Spitzer WJ, Krafft T. Results of surgical therapy of regional lymph nodes in lower lip cancer. *Fortschr Kiefer Gesichtschir* 1992; 37: 77-8.
- Stein AL, Tahan SR. Histologic correlates of metastasis in primary invasive squamous cell carcinoma of the lip. *J Cutan Pathol* 1994; 21(1): 16-21.
- Zitsch RP 3rd, Park CW, Renner GJ, Rea JL. Outcome analysis for lip carcinoma. *Otolaryngol Head Neck Surg* 1995;113(5): 589-96.

Received: 18 04 2005
Accepted for publishing: 20 08 2005